

## LETTERS TO THE EDITOR

### EPIDURAL EMPHYSEMA ASSOCIATED WITH SEVERE THORACIC TRAUMA

Dear Sir,

The presence of air in the spinal canal (pneumorachis) associated with pneumomediastinum is a rare occurrence<sup>1-6</sup>, being exceptional if presented together with pneumothorax<sup>7</sup>.

Below we report a case of epidural emphysema as shown in the CAT scan of patient as a result of a traffic accident.

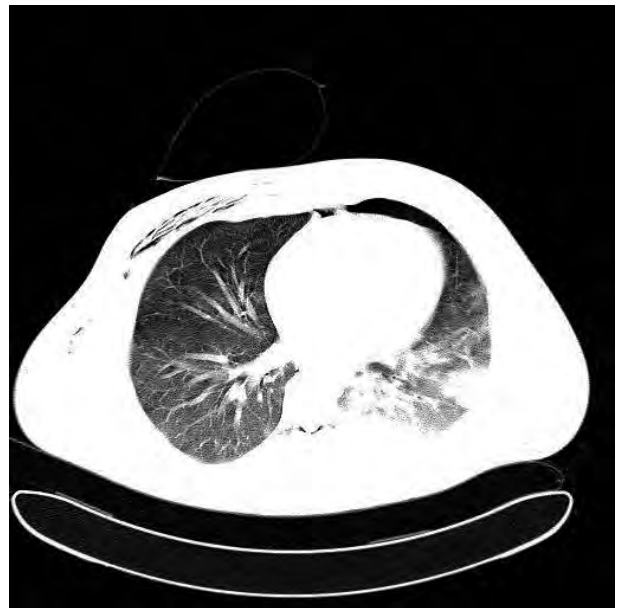A 36-year-old male, with no relevant clinical history was referred to our hospital after having been injured in a traffic accident. The patient presented with general malaise, tachypnea and respiratory indrawing. Upon arrival he had 30 breaths per minute, 90% oxygen arterial saturation (pulsioxymetry), BP 110/70 and crackling of the anterior wall of the right hemothorax upon exploration, with reduced vesicular murmur. The neurological exploration was completely normal. Orotracheal intubation was performed and, once the patient was stabilised, the chest CT scan showed left anterior pneumothorax, subcutaneous emphysema in the anterior thoracic region and an air bubble in the spinal canal at level D2-D8.

Several causes that may lead to pneumothorax include: MDMA/Ecstasy consumption<sup>8,9</sup>, abscesses, asthma or cough attacks, violent vomiting, epidural anaesthesia, lumbar puncture, chest surgery or trauma and spinal surgery<sup>7,10,11</sup>. Less frequently it may be associated with meningitis or pneumocephalus<sup>7,12</sup>. Epidural emphysema with pneumothorax and pneumomediastinum is an extremely rare occurrence as has already been mentioned, with a generally benign spinal-neurological prognosis in this case.

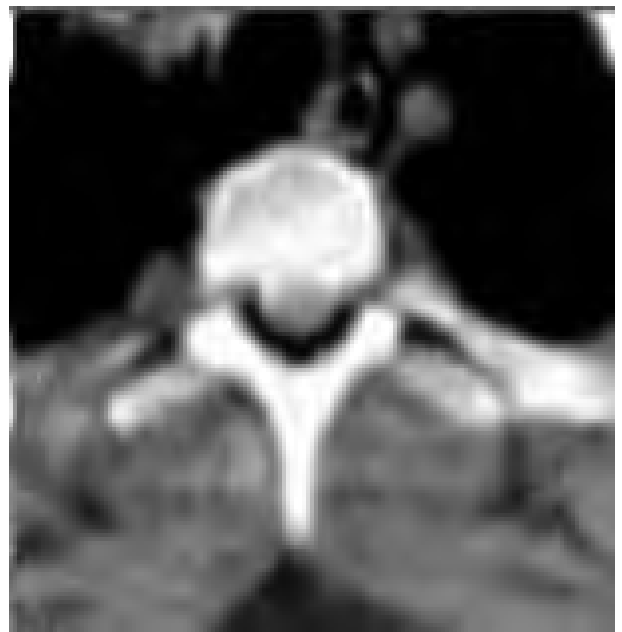Epidural pneumorachis generally happens as a result of two factors: either directly with the air reaching the epidural space via a needle, or via the posterior mediastinum. In the latter case, air is diffused from the posterior mediastinum and/or retropharyngeal space to the epidural space with hardly any resistance, via the fascial planes and the vertebral foramina<sup>6</sup>. In any case its presence is often asymptomatic and in most cases is a chance finding which spontaneously remits after a few weeks. Nevertheless, in some cases it can yield symptoms similar to an ictus, and must thus be monitored<sup>12</sup>.

## References

- 1 Drevelengas A, Kalaitzoglou I, Petridis A. Pneumorrhachis associated with spontaneous pneumomediastinum. *Eur J Radiol* 1994;18:122-3.



**Figure 1.** Lung axial section with window. Air in right anterior thoracic wall is observed. Left anterior pneumothorax. Pulmonary contusion on left base and air in epidural space at level D8 (pneumorachis).



**Figure 2.** Mediastinum axial section with window centred on D2. Detail of pneumorachis.

- 2 Tsuji J, Takazakura E, Terada Y, et al. CT demonstration of spinal epidural emphysema complicating bronchial asthma and violent coughing. *J Comput Assist Tomogr* 1989;13:38-9.
- 3 Willing SJ. Epidural pneumatosis: a benign entity in trauma patients. *AJNR Am J Neuroradiol* 1991;12:345.

- 4 Yoshimura T, Takeo G, Souda M, et al. CT demonstration of spinal epidural emphysema after strenuous exercise. *J Comput Assist Tomogr* 1990;14:303-4.
- 5 Dosis T, Fitas A, Zarifis G. Spontaneous epidural emphysema and pneumomediastinum. *Eur J Cardio-thorac Surg* 2000;18:123.
- 6 Defouilloy C, Galy C, Lobjoie E, Strunski V, Ossart M. Epidural pneumatosis: a benign complication of benign pneumomediastinum. *Eur Respir J* 1995;8:1806-7.
- 7 Katz DS, Groskin SA, Wasenko JJ. Pneumorrhachis and pneumocephalus caused by pneumothorax and multiple thoracic vertebral fractures. *Clin Imaging* 1994;18:85-7.
- 8 Bernaerts A, Verniest T, Vanhoennacker F et al. Pneumomediastinum and epidural pneumatosis after inhalation of "Ecstasy". *Eur radiol* 2003;13:642-3.
- 9 Mutlu H, Silit E, Pekkaflali Z, Incedayi M, Basekim C, Kizilkaya E. "Ecstasy" (MDMA) induced pneumomediastinum and epidural pneumatosis. *Diagn Intervent Radiol* 2005;11:150-151.
- 10 Kapur A, Sandhu S. Epidural pneumatosis : not necessarily benign. *AJNR Am J Neuroradiol* 1994;15:195-6.
- 11 Aribas OK, Gormus N, Kiresi DA. Epidural emphysema associated with primary spontaneous pneumothorax. *Eur J Cardio-thorac Surg* 2001;20:645-6.
- 12 Ristagno RL, Hiratzka LF, Rost RC. An unusual case of pneumorrhachis following resection of lung carcinoma. *Chest* 2002;121:1712-4.

**Ramón PALACIOS BOTE\***,  
**Antonio MARTÍNEZ MORENO\***,  
**Juan María FERNÁNDEZ NÚÑEZ\*\***,  
**Miguel CARDENAL FALCÓN\*\***,  
**María Rosario PEINADO CLEMENS\*\***,  
**Eduardo JIMÉNEZ LÓPEZ\*\*\***

\*Radiology Department. \*\*Emergency Department.  
 Hospital Infanta Cristina. Badajoz, Spain.

\*\*\*Emergency Department, Hospital Tierra de Barros  
 de Almendralejo. Badajoz, Spain.

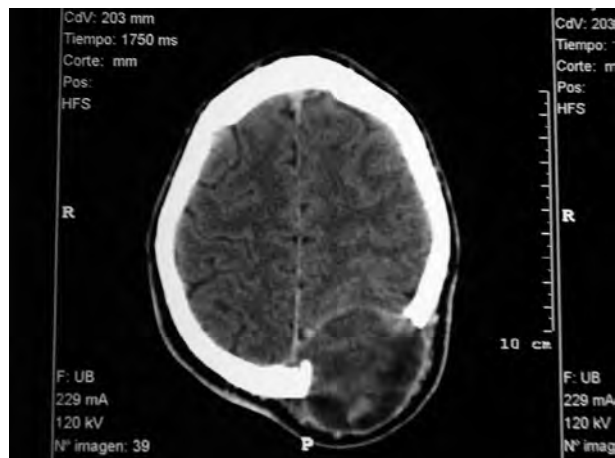
## CRANIAL MYXOFIBROSARCOMA

Dear Sir,

Myxofibrosarcoma is a myxoid variant of malignant fibrous histiocytoma (MFH), a fibroblastic lesion of myxoid stroma of a subcutaneous or deep location<sup>1,2</sup>.

These sarcomas normally present on the limbs<sup>3</sup>, although they can appear in any anatomical area<sup>4</sup>. MFH is a high-grade sarcoma that accounts for 1-3% of head and neck sarcomas, with the myxoid variant or myxofibrosarcoma being exceptional<sup>5</sup>.

On account of its unusual and evident appearance, we present the case of a 22-year-old male presenting at traumatology emergency services with headaches and tumoration in the left parietal-occipital region, palpable, visible and of a large size, which he began to notice 5 months previously. Upon admission he was haemodynamically stable, eupneic, afebrile, conscious, oriented



**Figure 1.** Computerized tomography of cranium showing an extra and intracranial mass located in the left parietal-occipital region.

and cooperative; GCS: 15 points. No alterations in upper functions, no alteration of cranial pairs and no motor or sensitive focality. The computerized tomography of the cranium detected an extra and intra cranial mass in the left parietal-occipital region, with erosion and lysis of the cranial vault (Figure 1). The angio MRI showed low vascularisation of the tumour but compression in the upper longitudinal sinus, although without complete obstruction.

Surgical intervention involved left occipital craniectomy, extirpating the affected bone and fleshy tumour in full which, although adhered to the dura mater, did not invade it. A Palacos acrylic cranioplasty was performed, set with central stitches and titanium microplates fixed with screws.

The anatomic-pathological report described a myxofibrosarcoma of an intermediate histological grade destroying the bone, and delimited by the dura mater and the subcutaneous fascia. This type of tumour has a low infiltration peripheral growth pattern, and in this case it seems that it did not manage to infiltrate the lateral edges.

## References

- 1 Weiss SW, Enzinger FM. Myxoid variant of malignant fibrous histiocytoma. *Cancer* 1977;39:1672-85.
- 2 Angervall L, Kindblom LG, Merck C. Myxofibrosarcoma. A study of 30 cases. *Acta Pathol Microbiol Scand (A)* 1977;85:127-40.
- 3 Merck C, Angervall L, Kindblom LG, Oden A. Myxofibrosarcoma. A malignant soft tissue tumor of fibroblastic histiocytic origin. A clinicopathologic and prognostic study of 110 cases using a multivariate analysis. *APMIS* 1983;91(suppl 282):1-40
- 4 Zapater E, Bagan JV, Campos A, Martorell M, Basterra J. Malignant fibrous histiocytoma of the head and neck. Case

report. Bull Group Int Rech Sci Stomatol Odontol 1995;38:121-4.

5 Pandey M, Chandramohan K, Thomas A, et al. Soft tissue sarcoma of the head and neck region in adults. Int J Oral Maxillofac Surg 2003;32:43-8.

**Francisco Javier GUTIÉRREZ CARACUEL,  
Inmaculada APONTE TOMILLO,  
Antonia VÁZQUEZ GONZÁLEZ,  
Amparo GARCÍA FALCÓN**

*Critical Care and Emergency Unit. Orthopaedics and  
Traumatology Hospital. H.H.U.U. Virgen del Rocío.  
Seville, Spain.*

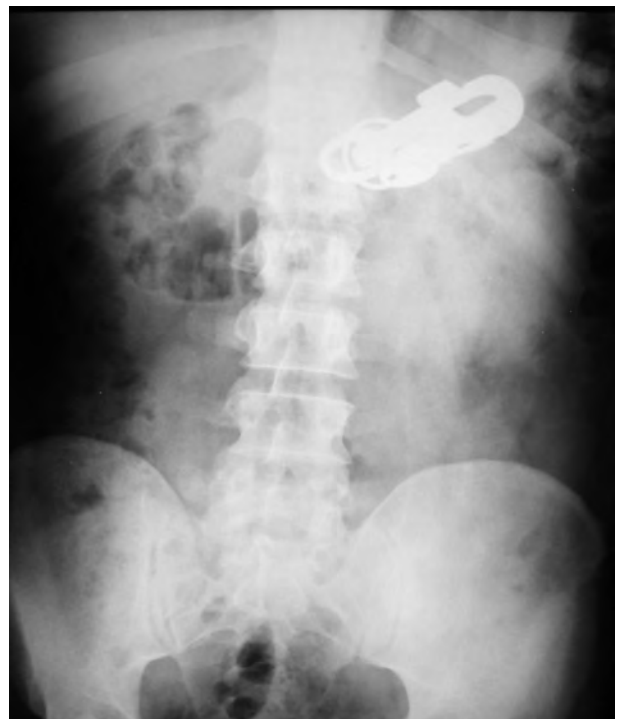## UNUSUAL FOREIGN OBJECT IN STOMACH

Dear Sir,

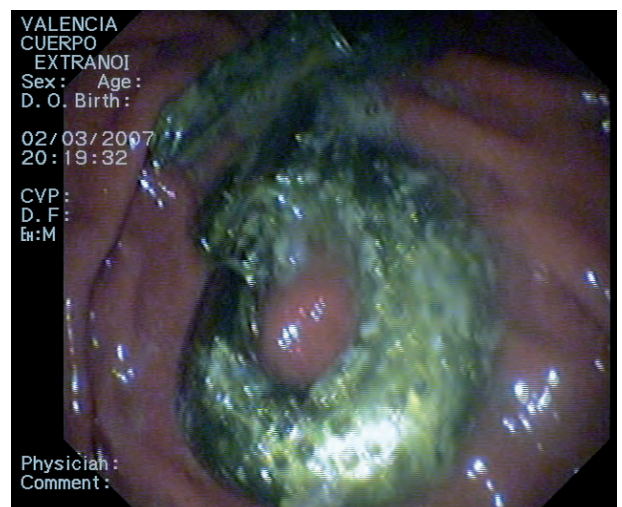Here we present the case of a 27-year-old male, with no relevant medical history, who presented at emergency services after the accidental ingestion of a foreign body (FB) three days previously and reported that he was handling a key hooked on a carabiner-style keychain, using it as a toothpick, and on exiting the room was accidentally hit by the access door in the face, resulting in the sudden ingestion of the object (keychain plus three keys). After an anodyne exploration, a radiological study showed the presence of a radio-opaque FB in the gastric cavity (Figure 1). The patient underwent an upper digestive endoscopy under intravenous sedation identifying the FB in the gastric lumen, with the underlying mucosa in good condition (Figure 2). Evacuation was performed by polypectomy snare (Figure 3), with the keychain splitting into two pieces when passing through the cardias; both parts were extracted with no complications (Figure 4). The patient was discharged with no further problems after twelve hours observation.

Different FBs can be lodged in the digestive tract, either by accident or deliberately. Almost 90% of the FBs ingested spontaneously pass through the main intestinal barriers, for subsequent natural elimination. The remaining 10% are elements of different types (coins, bottle tops, toothpicks, needles, spoons, razor blades, metal tweezers, etc) and/or potentially toxic (batteries) which can be extracted via endoscopic procedures. Surgery is used only in 1% of the cases. Serious complications in FB ingestion include intestinal obstruction, haemorrhage, perforation and intra-abdominal abscesses<sup>1,2</sup>.

FBs in the oesophagus usually require extraction six hours before the last food intake. By contrast, objects are often retained in the gastric cavity for long periods with no symptoms and, depending on the nature of the FB, treatment may be expectant. Endoscopic extraction is possi-

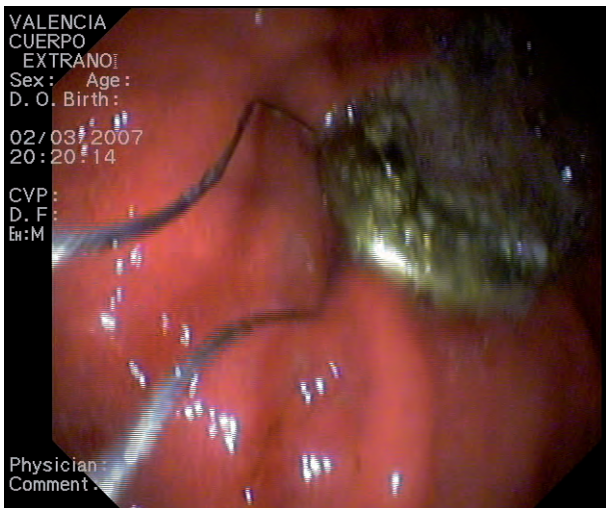


**Figure 1.** Simple x-ray of abdomen showing foreign body.

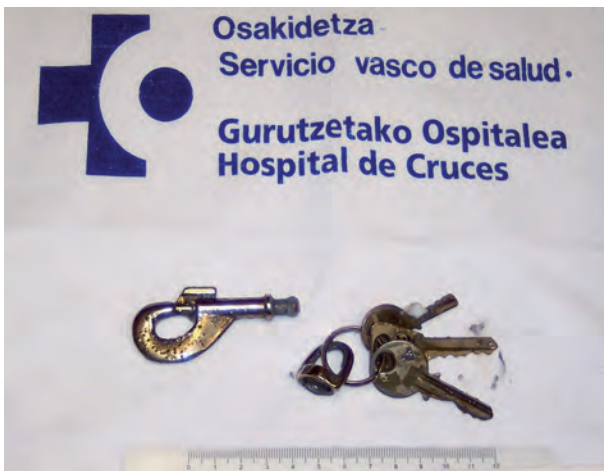

**Figure 2.** Upper digestive endoscopy of patient showing underlying mucosa in good condition.

ble most of the time by means of flexible endoscopy, using different types of tongs (polypectomy snare, foreign body forceps, "crocodile" grips, Dormia extractor, etc) to grip the FB by the least sharp end, whilst moving closer to the endoscope and blowing air constantly when passing through the oesophagus to prevent lesions in that area. The process is simplified with the use of wider diameter therapeutic endoscopes and occasionally by an "over-tube"<sup>3,4</sup>.



**Figure 3.** Evacuation via polypectomy snare.



**Figure 4.** Extracted foreign bodies.

## References

- 1 Hunter TB, Taljanovic MS. Foreign Bodies. *Radiographics* 2003;23:731-57.
- 2 Eisen GM, Baron TH, Dominitz JA, Faigel DO, Goldstein JL, Johanson JF, et al. Guideline for the management of ingested foreign bodies. *Gastrointest Endosc* 2002;55:802-6.
- 3 Chaves DM, Ishioka S, Felix VN, Sakai P, Gama-Rodrigues JJ. Removal of a foreign body from the upper gastrointestinal tract with a flexible endoscope: a prospective study. *Endoscopy* 2004;36:887-92.
- 4 Li ZS, Sun ZX, Zou DW, Xu GM, Wu RP, et al. Endoscopic management of foreign bodies in the upper-GI tract: experience with 1088 cases in China. *Gastrointest Endosc* 2006;64:485-92.

**Manuel CUESTA MARTÍN<sup>1</sup>,  
Ignacio CASADO MORENTIN<sup>2</sup>,  
Eunate ARANA ARRI<sup>1</sup>,  
Aitor GARCÍA DE VICUÑA MELÉNDEZ<sup>1</sup>**

<sup>1</sup>Emergency Department. <sup>2</sup>Gastrointestinal Medicine Department. Hospital de Cruces. Baracaldo. Vizcaya, Spain.

## OCCUPATIONAL STRESS: QUALITY OF INTERPERSONAL RELATIONSHIPS IN WORK TEAMS

Dear Sir,

We are an emerging, multidisciplinary research team, of mostly senior physicians in the 061 SCS Emergency Services and we are concerned about the quality of interpersonal relationships and the highly frequent situations of occupational stress<sup>1-3</sup>.

We believe that something should what is called for it not acting on it when it happens, but identifying causes and applying solutions. In this regard, in one of the last issues of EMERGENCIAS<sup>4</sup> it was suggested that "prevention over time, from training of house doctors, combining technical and scientific training with that of a psychosocial nature, requires tutors with good instrumental and emotional abilities". This may be so, but how many tutors fit such a profile?

It is true that a good working environment requires appropriate working conditions, as well as something else. We believe that it is the commitment of the professionals within unified work teams. What makes professionals feel fulfilled by their work? What makes professional feel like people and not mere numbers? What is it that emotionally exhausts us?

Managers know full well that work teams are a good management tool and, as leaders, they recognise their importance. However, to belong to a team also means interdependence and thus almost certainly confrontations which, depending on the approach taken, shall have a more or less beneficial outcome for the parties involved. Who has never had problems? Problems due to unclear information, exclusion, poorly defined roles, invasion of authority, lack of abilities, lack of respect...? What should be done then? That is the question!

Is it worth demanding changes or is it not worth while? This depends. It sounds like science fiction but there are some who believe that the feeling of belonging to a group is based on giving and taking; cooperation in the face of competition; maintaining unity by means of respectful, empathetic and non-aggressive communication; on having the chance to express one's ideas; on feeling listened to; on making decisions, taking part in meetings that are non-aggressive, constructive and geared to solving problems; on agreeing that there are problems to be solved and how to solve them; on celebrating successes, sharing projects; on feeling that what we do is worth while and feeling recognised for our work. From this

point of view, a team can serve as a good protection measure against occupational stress.

This is not an easy task; most often we will find that empathy is not part of our vocabulary and that "creative, innovative and non-hostile environments" are pie in the sky. This is why we believe in the usefulness of training in relationship skills such as counselling<sup>5</sup>, the efficacy of which has been proven in situations of great emotional overload, such as in Palliative Care Units<sup>6</sup>. The main objectives of health professionals are the same as those of counselling: reduction of people's suffering when adapting to new stressful situations, to take care of oneself in order improve the degree of satisfaction of professionals, patients and families.

Counselling is a skill that can be learned; it is based on ethics, assertive communication, emotional support, self-regulation and problem solving. It involves one's personal effort in reviewing one's attitude, admitting one's own contribution to the root of the problem, questioning, not presupposing, identifying specific needs, tackling fears, understanding emotions and, why not?... asking for help!

It is clear that as professionals we cannot give what we would like to receive as patients when we are overwhelmed with apathy, emotional exhaustion, depersonalised and unfulfilled at work. Occupational stress of a multifactorial origin which affects house doctors, consultants, nurses, technicians, administrative staff, phone operators, ancillary staff and porters alike.... each at his/her own level of responsibility. In the words of Eric

Cassell, "What suffers are not the bodies, it is the people". We must do something!

## References

- 1 Fernández O, Hidalgo C, Martín A, Moreno S García del Río B. *Burnout* en médicos residentes que realizan guardias en un servicio de urgencias. *Emergencias* 2007;19:116-21.
- 2 Casado A, De Lucas N, López-Fernández E, Sánchez A, Jiménez JA. Lipid peroxidation, occupational stress and aging in workers of a prehospital emergency service. *Eur J Emerg Med* 2006;13:165-71.
- 3 Moreno E. Estrés ocupacional en los profesionales de la medicina aguda. *Emergencias* 2007;19:151-3.
- 4 Mingote JC, Gálvez M. El estrés del médico residente en Urgencias. *Emergencias* 2007;19:111-2.
- 5 Costa M y López E. Manual para la ayuda psicológica. Dar para poder vivir. Más allá del counselling. Madrid: Pirámide, 2006.
- 6 Arranz P, Barbero JJ, Barreto P y Bayés R. Intervención emocional en cuidados paliativos Modelo y protocolos (2ª ed). Barcelona: Ariel, 2005.
- 7 Cassell EJ. The nature of suffering and the goals of medicine. *New Engl J Med* 1982;306:639-45.

**María Cruz GUTIÉRREZ DÍEZ<sup>1</sup>,  
Ana SANTAMARÍA PABLOS<sup>2</sup>,  
Abrahám DELGADO DIEGO<sup>1</sup>,  
José Antonio MORENO MARÍN<sup>1</sup>,  
Ana María MONASTERIO RENTERÍA<sup>1</sup>,  
Milagros LANDALUCE FUENTES<sup>1</sup>,  
Carlos REDONDO FIGUERO<sup>3</sup>**

<sup>1</sup>061 Primary Care Emergency Services, Servicio Cántabro de Salud. Spain. <sup>2</sup>University of Granada. <sup>3</sup>Centro Salud Vargas, Santander, Servicio Cántabro de Salud. Universidad de Cantabria, Spain.