

LETTERS TO THE EDITOR

Traumatic intercostal pulmonary hernia

Sir,

Pneumocele is defined as the protrusion of a portion of lung parenchyma through an abnormal opening of the chest wall. The herniated segment is almost always covered by parietal pleura to form the bag and the skin cover. Pneumocele can be classified according to etiology as congenital and acquired; the latter in turn may be traumatic, postsurgical and spontaneous or pathological. Depending on location, it can be cervical, costal or diaphragmatic³. We present a case of costal lung hernia secondary to chest trauma. Symptoms are usually few and infrequent. The diagnosis is usually made by physical examination and can be confirmed using chest radiography or computed tomography (CT) scan.

The case involved a 73-year-old man with a history of hypertension, hypercholesterolemia, hiatus hernia, intermittent claudication, polyarthrosis, multiple rib fractures (2nd to 6th right ribs), adaptive anxiety-depression disorder, Parkinson's of unknown etiology and appendectomy. He visited the emergency department for left chest trauma following an accidental fall. He was tachypneic, with intense rib pain that increased with deep inspiration, Valsalva manoeuvres and palpation of the affected area; he was conscious and oriented, normally hydrated, afebrile, with blood pressure of 155/90 mmHg, heart rate of 84 beats per minute, without jugular vein engorgement, audible heart sounds with frequent extrasystole, breath sounds preserved bilaterally with right basal crackles, and unremarkable abdomen except for an appendectomy scar. Physical examination also showed moderate but noticeable left gynecomastia (not previously reported by the patient or relatives) with clear crepitus on palpation of the area, swelling and sub-mammary bruising extending to the anterolateral area.

Chest X-ray (Figure 1) showed left pulmonary contusion related to a fracture of the left 7th rib and image compatible with intercostal hernia of the 7th intercostal space and old rib fractures on right rib cage. Chest CT scan (Figure 1) confirmed the existence of a traumatic intercostal uncomplicated hernia without pneumothorax, hemothorax or pleural effusion. The patient was hospitalized for six days, with complete bed rest, oxygen therapy and analgesic treatment, without complications and showed good improvement. Follow up X-ray showed no evidence of chest complications; given

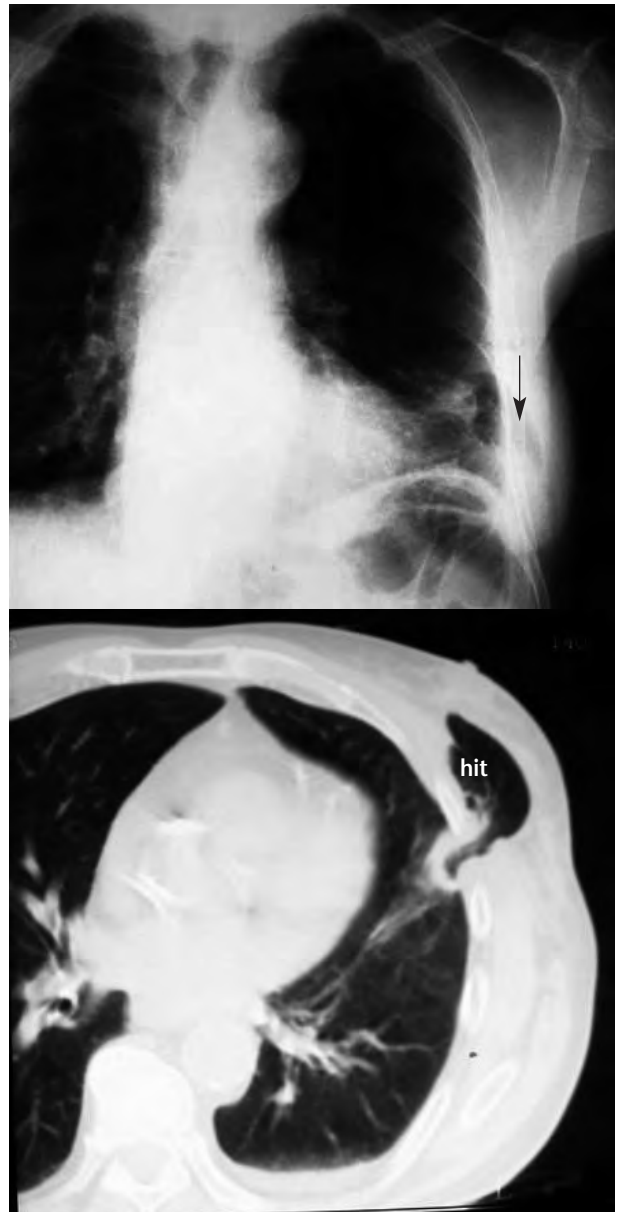

Figure 1. Plain chest X-ray (top) showing left lung contusion secondary to a fracture of the 7th left rib, and image compatible with intercostal hernia in the 7th left intercostal space (arrow). Computed tomography scan of the lower chest (below). Traumatic intercostal hernia (hit), uncomplicated and without pneumothorax, hemothorax or associated pleural effusion.

the good clinical outcome and agreement of the patient and family, surgery was ruled out in favour of a conservative approach.

Lung hernia is a rare entity, with approximately 300 cases reported in the literature⁴. According to Morel-Lavelle, it may be divided into congenital and acquired; the latter in turn may be pathological, traumatic or spontaneous. Spontaneous hernias are associated with manoeuvres involving extreme pressure on the chest wall (such as coughing or sneezing) causing the fracture of one or more ribs or intercostal muscle tear. Generally, this presents in patients with senile osteoporosis and / or chronic coughs. Protrusion of the lung wall may occur through the intercostal spaces (65% of cases), supraclavicular region (35% of cases)⁶ or through diaphragmatic wall defects (rare).

Traumatic lung hernia, such as in our case, is rare and mostly due to high-energy, blunt chest trauma⁵. It does not necessarily present immediately after the impact, and may appear months or even years later^{1,7}. The etiology may be explained by the anatomy of the intercostal spaces. The external and internal intercostal muscles that line the internal intercostal space are somewhat shorter than the ribs, so that one end of the space is covered by only one of the muscles and the other by aponeurosis (sinew). Intercostal spaces also have perforations through which chest wall vessels and nerves pass. Precisely these places are the most fragile parts of intercostal spaces, and the most susceptible to high pressure manoeuvres.

They do not represent a serious problem unless incarceration and / or strangulation occurs, which cause pain and sometimes haemoptysis⁸. Besides good clinical examination, diagnosis usually requires chest X-ray, with oblique projections being most useful⁹. However, the diagnostic tool of choice is chest CT scan since it allows visualization of the pneumocele, its exact location and the size of the chest wall defect^{10,11}.

With regard to therapeutic approach, there is sharp controversy¹². Some authors prefer a conservative approach with immobilizing bandage, and if this fails and / or complications arise, then opt for surgical repair. However, others claim that surgery is indicated in all anterior intercostal hernias, even if they are asymptomatic, by means of surgical repair or prosthetic (PTFE) patch repair with open surgery or thoracoscopy.

References

- 1 Taylor DA, Jacobson HG. Post-traumatic herniation of the lung. *Radio-logy*. 1962;5:896-9.
- 2 Morel-Lavelle A. Hernias du Pomon. *Bull Soc Chir Paris*. 1847;1:75.
- 3 Moncada R, Vade A, Gimenez C, Rosado W, Demos TC, Turbin R. Congenital and acquired lung hernias. *J Thorac Imaging*. 1996;11:75-82.

- 4 Reardon MJ, Fabre J, Reardon PR, Baldwin JC. Video-assisted repair of a traumatic intercostals pulmonary hernia. *Ann Thorac Surg*. 1998;65:1155-7.
- 5 Jiménez Aguero R, Hernández Ortiz C, Izquierdo Elea JM, Cabeza Sánchez R. Hernia pulmonar intercostal espontánea: aportación de un caso. *Arch Bronconeumol*. 2000;36:354-6.
- 6 Munnell ER. Herniation of the lung. *Ann Thorac Surg*. 1968;5(Supl):204.
- 7 Reynolds J, Davis JT. Injuries of the chest wall, pleura, pericardium, lung bronchi and esophagus. *Radiol Clin North Am*. 1966;4:383-401.
- 8 Francois B, Desachy A, Cornu E, Ostyn E, Niquet L, Vignon P. Traumatic pulmonary hernia: surgical versus conservative management. *J Trauma*. 1998;44:217-9.
- 9 Allen GS, Fischer RP. Traumatic lung herniation. *Ann Thorac Surg*. 1997;63:1455-6.
- 10 Hauser M, Weder W, Largiader F, Glazer GM. Lung herniation through a postthoracoscopy chest wall defect: demonstratio with spiral CT. *Chest*. 1997;112:558-60.
- 11 Tamburro F, Grassi R, Romano R, Del Vecchio W. Acquired spontaneous intercostal hernia of the lung diagnosed on helical CT. *Am J Roentgenol*. 2000;174:876-7.
- 12 Goverde P, Van ZIL P, Van der Brande F, Vanmaele R. Chronic of the lung in patient with chronic obstructive pulmonary disease. Case report and review of the literature. *Thorac Cardiovasc Surg*. 1988;46:164-6.

Javier GIL DE BERNABÉ LÓPEZ¹,
Luis Manuel CLARACO VEGA¹,
Amos URTUBIA PALACIOS²,
María Isabel FERNÁNDEZ ESTEBAN³,
Pedro PARRILLA HERRANZ¹,
Javier GARCÍA TIRADO⁴

¹Servicio de Urgencias. Hospital Universitario Miguel Servet. Zaragoza, Spain. ²Servicio Urgencias. Hospital General Elda. Alicante, Spain. ³Médico de Familia. Área 16. Alicante, Spain. ⁴Servicio de Cirugía Torácica. Hospital Universitario Miguel Servet. Zaragoza, Spain.

Post-choking atelectasis

Sir,

Foreign body aspiration is a frequent problem and its consequences may range from mild to very severe, including cardiopulmonary arrest (CPA) from asphyxiation, depending on the location and degree of obstruction caused by the body sucked into the airway. It has a bimodal pattern, with a peak in infants aged less than one year and another in patients aged about 75 years. Any smallish object can be aspirated and such aspiration is especially associated with food intake. Most cases are resolved by coughing or basic resuscitation¹, but occasionally this is not enough and cardiopulmonary resuscitation (CPR) and post-resuscitation measures are needed.

PA 62-year-old patient choked while eating. On arrival of the out-of-hospital emergency services, the patient had CPA with asystole; after approximately 10 minutes of CPR, heart rate recovered. Prior to orotracheal intubation, a lump of bread was extracted from the airway. The patient was admitted to intensive care where X-ray showed com-

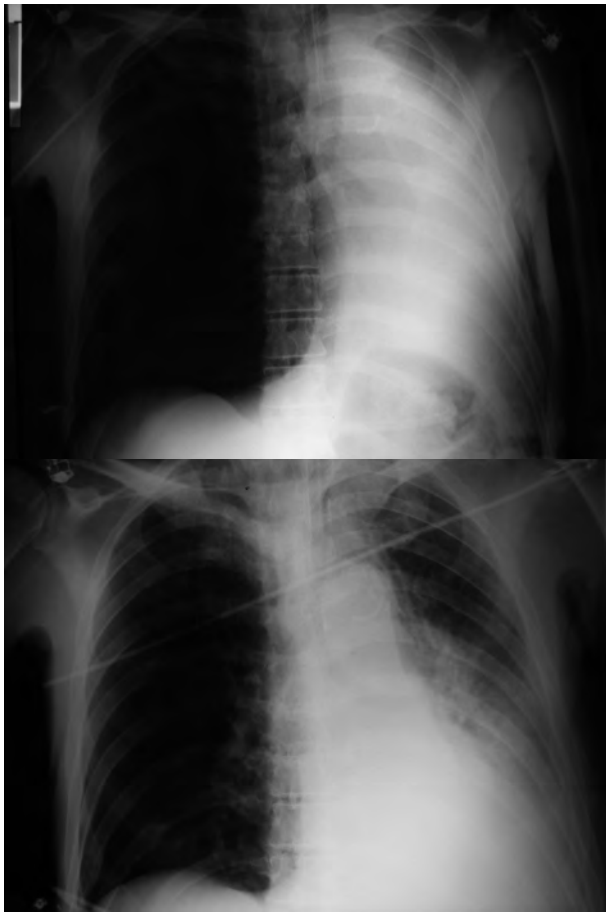


Figure 1. Admission chest X-ray (above) showing right lung atelectasia, and (below) X-ray after bronchoscopy showing subsequent evolution.

plete atelectasis of the right lung, partially resolved with bronchoscopy (Figure 1), during which more bread and copious secretions were removed.

The migration of aspirated foreign bodies into the tracheobronchial tree, most often to the right side, may cause obstructive atelectasis that requires bronchoscopy for resolution². Occasionally, long-standing aspiration of a foreign body with irreversible changes in the lung wall may require surgery³.

References

- 1 Handley AJ, Koster R, Monsieurs L, Perkins GD, Davies S, Bossaert L, et al. European Resuscitation Council Guidelines for Resuscitation 2005. Section 2. Adult basic life support and use of automated external defibrillators. *Resuscitation*. 2005;67(Supl. 1):S7-S23.
- 2 Sauret Valet J. Cuerpos extraños. *Arch Bronconeumol*. 2002;38:285-7.
- 3 Montero Cantú CA, Garduño Chávez B, Elizondo Ríos A. Broncoscopia rígida y cuerpo extraño. ¿Procedimiento obsoleto? *Cir Ciruj*. 2006;74:51-3.

Rosa María GARCÍA FANJUL,
Eva GARCÍA PINEY

*Servicio de Medicina Intensiva. Hospital de Cabueñes,
Gijón. Asturias, Spain.*

Protruding atrial thrombus in the left ventricle

Sir,

As recently published in EMERGENCIAS¹, ultrasound (US) as a diagnostic procedure can be most useful and we here suggest a number of potential indications for use in the emergency department conducted ED physicians². We present a case with rare US findings which significantly conditioned our therapeutic approach and probably averted dire consequences.

The patient was a 66 year-old woman without known cardiovascular risk factors, a history of atrial fibrillation (AF), treated with aspirin 100 mg/24 h and atenolol 25 mg/24 h. She was referred to our ED for fatigue and dyspnea with moderate exertion, with no other clinical symptoms. Physical examination and baseline laboratory results were normal, and with AF under control. Echocardiogram showed apparently normal contractility without valve lesions, but also dilated left atrium containing a mobile mass of 2 cm near the mitral annulus. The study was therefore completed with transesophageal echocardiography (Figure 1A) by the cardiology department, reporting a mobile thrombus occupying the left atrial appendage which protruded into the left atrium, crossing the mitral ring and visible in the left ventricle during diastole (Figure 1B). The patient received immediate treatment with enoxaparin (1 mg/kg/12 hours). During her hospital stay there was no embolic event with clinical impact. Transthoracic US follow up one week later showed no evidence of thrombus, and the patient initiated long-term anticoagulation therapy with warfarin. The patient was discharged with sinus rhythm.

In this case, there were no indication for anticoagulation factors before our echocardiographic findings, since the patient did not present risk factors classified as moderate (age \geq 75 years, hypertension, heart failure, low ejection fraction or diabetes mellitus) or high (previous stroke, arterial embolism, mitral stenosis or prosthetic heart valve), according to the ACC / AHA / ESC guideline recommendations of 2006 on the prevention of thromboembolic phenomena in AF³. It was the use of echocardiography in the emergency department that allowed us to suspect and then confirm the presence of atrial thrombus with very high risk of embolism in a patient with AF⁴⁻⁶ and initiate appropriate treatment immediately, thus avoiding potentially fatal consequences, especially thromboembolism.

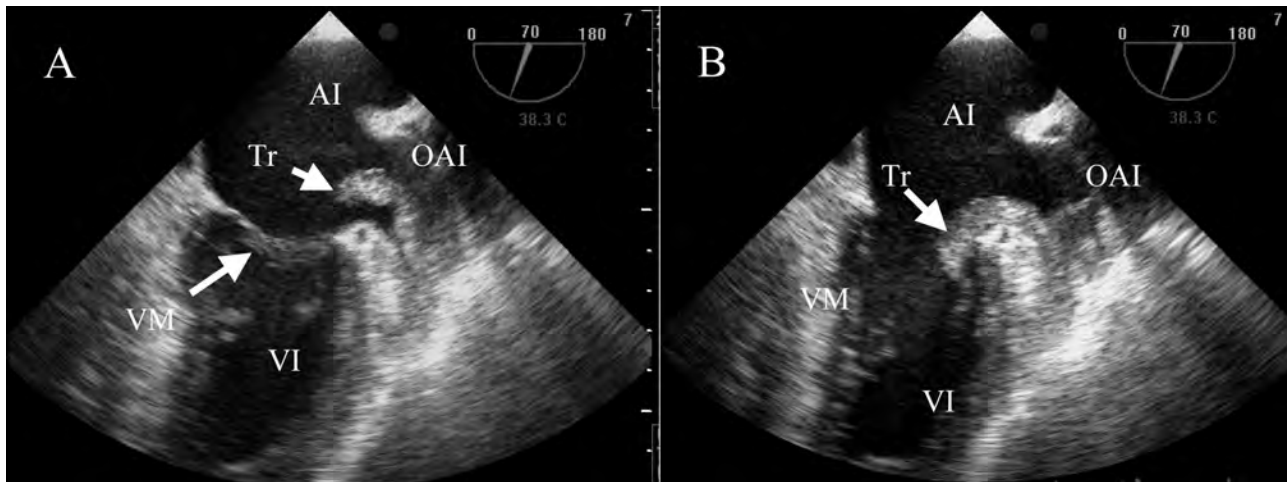


Figure 1. Transesophageal echocardiography. Panel A: Systole. Thrombus in the appendage which protrudes into the left atrium. Panel B: Diastole. The thrombus passed through the mitral ring and appears in the left ventricle. AI: left atrium; OAI: left atrium appendage; VI: left ventricle; Tr: thrombus. VM: mitral valve.

References

- 1 Nogué Bou R. La ecografía en medicina de urgencias: una herramienta al alcance de los *urgenciólogos*. *Emergencias*. 2008;20:75-7.
- 2 García Martín LA, Campo Linares R, Rayo Gutiérrez M. Pericarditis purulenta: diagnóstico ecográfico precoz en el servicio de urgencias. *Emergencias*. 2008;20:135-8.
- 3 New ACC/AHA/ESC Guidelines for the management of atrial Fibrillation: Highlighting Stroke Prevention. Nueva York: Medscape Cardiology; 2006.
- 4 García Quintana JA, González Morales L, Castro Bueno N, Medina Fernández-Acytuno. Tromboembolismo pulmonar con trombo móvil e la aurícula. *Med Intensiva*. 2006;30:183-6.
- 5 Gómez R, Penas, JL, Fleitas C, Cascallana JE. Trombo libre en aurícula izquierda. *Biomédica*. 2005;25:293-4.
- 6 Alexis Llamas J. Papel de la ecocardiografía convencional y transesofágica en la fibrilación auricular. *Rev Col Cardiol*. 2007;14(Supl. 3):165-70.

Rubén GÓMEZ IZQUIERDO¹,
Lorenzo ALONSO VEGA²,
Íñigo GÓMEZ ZABALA³,
Carlos TEJA SANTAMARÍA⁴

¹Servicio de Cardiología. ²Servicio de Urgencias.

³Médico de Familia. Hospital de Laredo. Cantabria, Spain.

Subacute headache in a young woman normal neurologic signs

Sir,

Headache is a frequent reason for consultation in the emergency department¹⁻³, and for daily practice it is important to differentiate between potentially dangerous causes and those which are not. In addition to the ever-important medical history, we must rely on neurologic examination and imaging techniques^{4,5}.

MWe present the case of a 34 year-old woman with

progressive headache of four days duration, holocraneal location and oppressive, which increased throughout the day, with periods of remission and unrelated to the Valsalva manoeuvre. She reported no vomiting or fever. She had suffered two spontaneous miscarriages in the previous five years. Physical examination and neurological examinations were unremarkable. Laboratory tests and chest X-ray were normal, with negative pregnancy test. Computed tomography (CT) scan revealed a hyperdense image in the right transverse and sigmoid venous sinuses (Figure 1). Nuclear magnetic resonance imaging (MRI) of the skull showed acute thrombosis of these sinuses. Jugular venous Doppler ultrasound showed alterations. She received anticoagulation with intravenous sodium heparin, and later with Coumadin, with good outcome. Thrombophilia test was normal [ESR, antithrombin III, D dimer, Protein C, Protein S, lupus anticoagulant, antibodies, hepatitis B and C, HIV, RPR, anti-Treponema pallidum, anticardiolipin and antinuclear antibodies (Ab), vitamin B12, folic acid, serum ferritin, immunoglobulin (Ig) A, G and M, plasma homocysteine, TSH, B2-microglobulin, V-Leiden gene factor and prothrombin mutation 202 106], so that the patient was finally diagnosed with idiopathic cerebral venous thrombosis (CVT).

LCVT is an underdiagnosed entity that may affect patients at any age, and both the clinical picture and neuroimaging techniques show great variability, which makes the diagnosis a real challenge^{2,3}. CT is the first test to be performed since it allows ruling out other causes as well as showing the underlying source; 80% will be abnormal, but CT findings are not always diagnostic. MRI is the technique of choice: MR venography increases the sensitivity of the study,

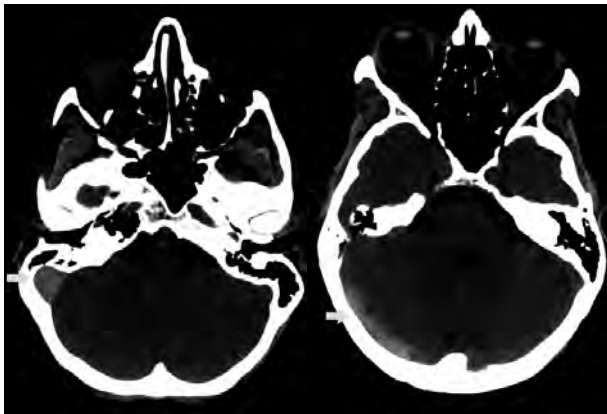


Figure 1. Cranial CT showing a hyperdense image at the sigmoid venous (arrow) and right transverse sinus (arrow).

and should be done before the suspicion of CVT, regardless of the CT result. Treatment is with anticoagulant therapy, sodium heparin in the acute phase followed by oral anticoagulation (INR2-3) for at least six months, when it becomes known as CVT without thrombophilic disorder^{4,5,7}. In conclusion, CVT is a potentially dangerous cause of headache that requires the use of complex imaging tests, and may be present despite normal neurological examination results.

Pablo FRANQUELO MORALES,
Margarita ALCÁNTARA ALEJO,
Carlos HERRÁIZ DE CASTRO,
Félix GONZÁLEZ MARTÍNEZ

*Servicio de Urgencias. Hospital Virgen de la Luz.
Cuenca, Spain.*

References

- 1 Dolera C, Peiro LZ, Antón JL, Navarro M. Trombosis de los senos venosos cerebrales: una emergencia neurológica poco frecuente. *Med Intensiva*. 2008;32:198.
- 2 Sánchez JP, Espina Riera B, Valle San Román N, Gutiérrez Gutiérrez A. Trombosis de los senos venosos cerebrales. *Medicine*. 2003;8:4987-94.
- 3 Laín Terés N, Julián Jiménez A, Núñez Acebes AB, Barrero Raya C, Aguilar Florit JL. Trombosis venosa cerebral. Un realiad en Urgencias. *Emergencias*. 2007;19:99-103.
- 4 González Hernández A, Fabre Pi O, López Fernández JC, Arana Toledo V, López Veloso C, Suárez Muñoz J. Prevalencia de los trastornos de la coagulación en una serie de trombosis de senos venosos cerebrales. *Rev Neurol*. 2007;45:661-4.
- 5 González Martínez F. Cefalea. En: Moya Mir MS, editor. *Manejo Integral de las Urgencias*. Madrid: Adalia Ed; 2007. p. 67-71.
- 6 Pérez D, Cambra L, Noguera Julián A, Palomeque Rico A, Toll Costa T, Campistol J, et al. Trombosis venosa cerebral en niña portadora de la mutación 20210GA del gen de la protrombina, tratada mediante fibrinólisis local del seno sagital superior. *Rev Neurol*. 2002;35:913-7.
- 7 Manzano P, Egido H, Sáiz A, Jorquera M. Ataque isquémico transitorio como expresión de trombosis de senos venosos duros. *Neurología*. 2006;21:155-8.

Subphrenic abscess

Sir,

An 80 year-old man was admitted to the emergency department with abdominal pain and febrile syndrome. Medical history included an episode of acute gallstone cholecystitis two months before with favorable evolution after conservative treatment. On arrival at the ED, physical examination revealed no abdominal pain on palpation, no peritonitis, and a body temperature of 37.2 ° C. Chest X-ray showed a level of fluid in the upper quadrant suggestive of right subphrenic abscess (Figure 1). Abdominal ultrasound showed a right subdiaphragmatic collection of 14 cm in diameter, near the midline, with abundant echogenic content containing air related with a subphrenic abscess. The gallbladder was not identified. The study was completed with computed tomography (CT) scan (Figure 1), which showed anterior subphrenic collection with hydro-aerial level and a 9 cm lesion in the vesicular

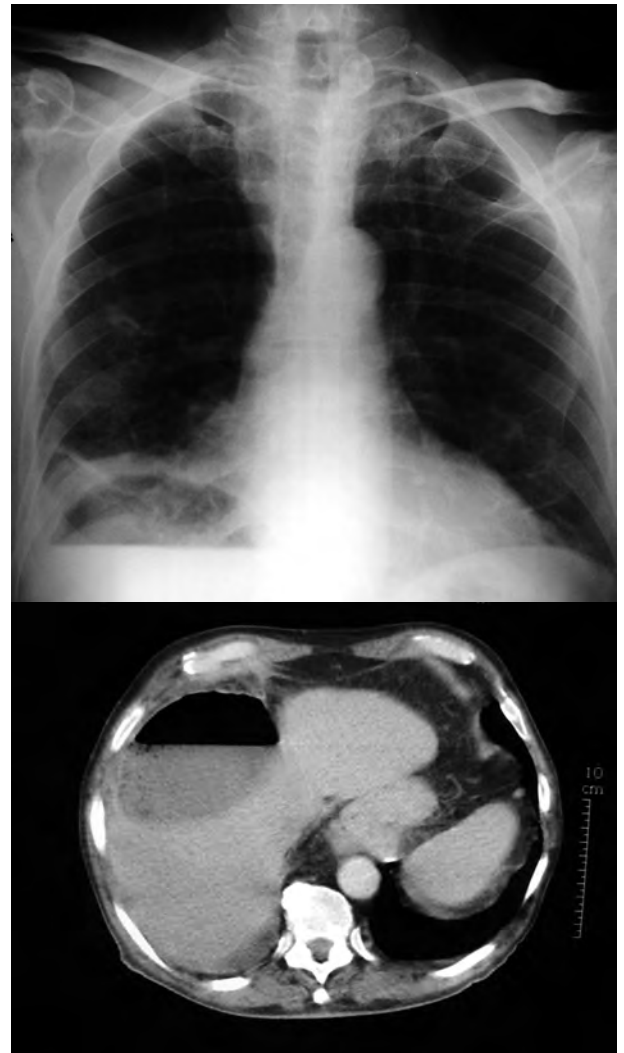

Figure 1. Chest X-ray (upper image) showing a hydro-aerial level in the right upper quadrant suggestive of subphrenic abscess, confirmed by CT scan (lower image).

bed, with air and multiple images suggestive of calcium stones. We performed puncture and aspiration of the lesion which drew out purulent fluid, so a percutaneous drain was placed. The final diagnosis was cholecystitis complicated by a subphrenic abscess.

For the diagnosis of subphrenic abscess it is especially important to correlate information obtained from medical history, examination, laboratory data and the findings of imaging tests. One needs to bear in mind that the existence of septic intra-abdominal or pelvic inflammatory processes, hollow visceral perforations, abdominal trauma - primarily of the hypochondria - or abdominal surgery may favour the development of this picture. Thus subphrenic abscess should be suspected in any patient with a history such as that here described and the signs and symptoms of sepsis; physical examination shows limited respiratory movements, pain on compression of the base of the chest, upper quadrant percussion pain or elevation of the hemidiaphragm on the affected side. Treatment is aimed at controlling sepsis with antibiotics and abscess drainage either percutaneously under ultrasound or CT control, or surgery.

References

- 1 Gervais DA, Ho CH, O'Neill MJ, Arellano RS, Hahn PF, Mueller PR. Recurrent abdominal and pelvic abscesses: incidence, results of repeated percutaneous drainage, and underlying causes in 956 drainages. *Am J Roentgenol.* 2004;182:463-6.
- 2 Cinat ME, Wilson SE, Din AM. Determinants for successful percutaneous image-guided drainage of intra-abdominal abscess. *Arch Surg.* 2002;137:845-9.

Estela FERNÁNDEZ CUADRIELLO,
 Ángela MEILÁN MARTÍNEZ,
 Bonel ARGÜELLES GARCÍA,
 Susana Ana ÁLVAREZ GONZÁLEZ
*Servicio de Urgencias. Hospital Universitario
 Arnau de Vilanova. Lleida, Spain.*

Chiladiti sign

Sir,

Chilaiditi sign is a rare radiological finding that may be confused with images leading to misdiagnosis of chest and abdominal trauma.

A 45 year-old man with unremarkable medical history was admitted to our centre after a motorcycle accident in which he crashed into a wall. Initial examination showed: Glasgow Coma Scale score of 15, blood pressure 140/80 mmHg, heart rate 93 bpm, respiratory rate 30 rpm, arterial SaO₂ 96% and FiO₂ 0.5. He presented chest pain, left dorsal erosion

and hypophonesis, subcutaneous emphysema, good mechanical ventilation without cervical tracheal deviation or jugular engorgement, correct cardiac auscultation and pulses, abdomen soft and depressible, without pain or peritonitis, and stable pelvis, no evidence of spinal injury, with multiple contusion and erosion of the limbs. Plain chest X-ray showed a small pneumothorax and left pleural effusion, fractured left ribs 3, 4, 5, 6, 7, and an image of air between the liver and the diaphragm on the right (Figure 1) obtained with computed tomography (CT) scan which was diagnosed as Chilaiditi sign. Follow up CT studies showed left lung contusion and a space-occupying hepatic lesion, compatible with hemangioma. After chest drainage, epidural analgesia and ventilatory physiotherapy, he regained physiological respiration.

Chilaiditi sign is found in 0.28% of standing chest X-rays¹, predominantly in men over 65 years of age². First described in 1910 by the radiologist Demetrius Chilaiditi Demetrius, it is a positional anomaly of the colon, and rarely the small intestine, characterized by the interposition of a loop of the colon between the right hemidiaphragm and the liver³, rarely found on the left side⁴. It is usually asymptomatic although some patients report abdominal discomfort, insidious constipation and nausea that are usually self-limiting, although the clinical relationship with the colon interposition is controversial³. As predisposing factors, certain authors have cited liver atrophy, abnormal colon position and elongation, paralysis of the phrenic nerve, hypothyroidism, obesity and mental disorders⁴. The emergence of volvulus⁵ is a rare complication. The absence of abdominal symptoms, or free intra-abdominal fluid/gas on Eco FAST and CT scan in the ED in our case, ruled out pneumoperitoneum. Despite the scarce clinical symptoms associated with traumatic diaphragmatic hernia⁶ and the limited diagnostic capacity of X-ray and CT scan for this condition⁷, radiological study and the mechanism of impact with high left chest injuries, less frequent on the right (5 - 20% of traumatic diaphragmatic rupture (0.8 to 3.6%)⁸, right traumatic diaphragmatic rupture with herniation of bowel contents was considered unlikely. Other lesions such as subphrenic abscess or hydatid cyst⁹ were ruled out by the absence of findings in the laboratory tests and medical history. Some authors recommend supine chest x-ray for diagnosis¹⁰. The use of CT scan helps to confirm the diagnosis. Caution should be taken when performing invasive techniques in the

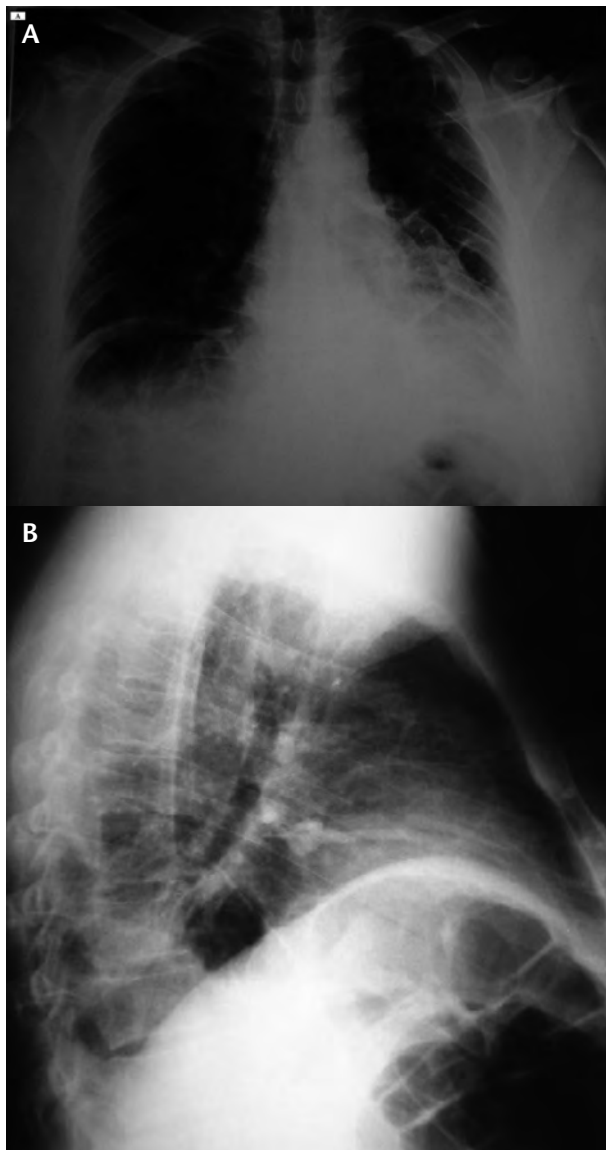


Figure 1. Chest X-ray: A) Note the right subdiaphragmatic air and right rib fractures and left pleural effusion. B) Lateral view in which the haustral folds were identified.

area, such as liver biopsy, to avoid iatrogenic lesions¹⁰.

Jordi MELÉ OLIVÉ,
 Fernando HERRERÍAS GONZÁLEZ,
 Cristina GAS RUÍZ,
 Enrique SIERRA GRAÑÓN

Servicio de Cirugía General y Aparato Digestivo. Hospital Universitario Arnau de Vilanova. Lleida, Spain.

References

- 1 Vessal K, Borhanmanesh F. Hepatodiagrammatic interposition of the intestine (Chilaiditi's syndrome). *Clin Radiol.* 1976;27:113-6.
- 2 Torgensen J. Suprahepatic interposition of the colon and volvulus of the coecum. *Am J Roentgenol.* 1951;66:747-51.
- 3 Tzimas T, Baxevanos G, Akritidis N. Chilaiditi's Sign. *Lancet.* 2009;373:836.
- 4 Kamiyoshihara M, Ibe T, Takeyoshi I. Chilaiditi's Sign mimicking a traumatic diaphragmatic hernia. *Ann Thorac Surg.* 2009;87:959-61.
- 5 Haddad CJ, Lacle J. Chilaiditi's syndrome: a diagnostic challenge. *Postgrad Med.* 1991;89:249-50.
- 6 Mele Olive J, Nogué Bou R. Rotura diafragmática traumática asociada a gastro-colo-espleno-tórax. *Emergencias.* 2005;17:96-7.
- 7 Rodríguez Morales G, Rodríguez A, Shatney CH. Acute rupture of the diaphragm in blunt trauma: analysis of 60 patients. *J Trauma.* 1986;26:438-44.
- 8 Kozak O, Menten O, Harlak A, Yigit T, Kilbas Z, Aslan I, et al. Late presentation of blunt right diaphragmatic rupture (hepatic hernia). *Am J Emerg Med.* 2008;26:638.
- 9 Shridar G, Leow CK. Free air or colon? *Ann Coll Surg.* 2003;7:136-8.
- 10 Prassopoulos PK, Raissaki MT, Gourtsoyiannis NC. Hepatodiaphragmatic interposition of the colon in the upright and supine position. *J Comput Assist Tomogr.* 1996;20:151-3.