

LETTERS TO THE EDITOR

Usefulness of activated recombinant factor VII in traumatic massive bleeding trauma: case report

Sir,

Hemorrhagic shock remains the leading cause of preventable death in patients with multiple injuries, responsible for 35%-40% of deaths secondary to massive blood loss¹. Early recognition of shock, rapid replenishment of blood volume and urgent surgery are essential to minimize multiorgan failure, morbidity and mortality².

Currently available recombinant factor VII (rFVIIa; NovoSeven®) may be useful in patients with multiple injuries or dilutional coagulopathy, due to its ability to bind to tissue factor (TF), and its action on platelets and fibrinolysis.

A 31 year-old man with no medical history of interest was admitted to our hospital ED after a road traffic accident. On arrival, the patient was unconscious, poorly perfused and tachycardic; during ambulance transfer he had received 1,500 ml crystalloid and 1,000 ml colloid. Hemodynamic stabilization was continued and he underwent computed tomography (CT) body scan which showed: fractures of the right jaw and condyle, maxilar, orbital floor, zygoma and zygomatic arch; pneumocephalus bilateral pneumothorax; left acetabular fracture, pubis fracture, fracture of the ileopubic and ilioischial branches, and secondary hematoma (500 ml), and right neck incised wound reaching to the vertebral bodies. During his stay in the ED, the patient received 6 concentrates of RBC, 2 units of platelets, 1 unit of plasma, vitamin K, tranexamic acid and more than 8 liters of crystalloid, colloid and hypertonic saline solution. For blood pressure maintenance he received repeated boluses of ephedrine and continuous infusion of norepinephrine. The emergency physicians contacted the pharmacy department to request the use of NovoSeven® given the poor clinical and hemodynamic state, while awaiting emergency surgery. Given the persistence and worsening of the situation and the impossibility of controlling different points of bleeding by the surgeons from the beginning of the intervention, it was decided to use factor

rVIIa (single dose of 100 mg / kg). In the following minutes external signs of bleeding stopped and coagulation values and acid-base balance were gradually normalized, which allowed the surgical team to continue the intervention and stabilize the different fractures with osteo-synthetic material. During subsequent evolution there were no more signs of coagulopathy and transfusion requirements decreased progressively. No thromboembolic events or episodes of disseminated intravascular coagulopathy developed. Laboratory tests on admission showed hemoglobin of 9.8 g / dl, Hematocrit 30%, platelets 97,000 / ul; INR 1.26, PA 69%, and pH 7.21. At the start of surgery, these values were: hemoglobin of 7.7 g / dl, hematocrit 23%, platelets 57,000 /ul, pH 7.19. After administration of NovoSeven®, coagulation improved to 1.68 INR and PA 51%.

Factor VII is a natural component of the process of coagulation, necessary to control and stop bleeding, as it participates in clot formation at the site of vascular injury to stop bleeding.

The Food and Drug Administration (FDA) first approved its use in 1999, and in 2005, ratified and extended and indicated it for bleeding episodes or surgical procedures in patients with hemophilia A or B and inhibitors of factor VIII or IX, and as treatment of bleeding episodes in patients with factor VII deficiency. All these Indications are also those currently approved by the Ministry of Health. Regarding its ability to promote hemostasis, the medical literature contains many reports confirming the increasing use of rFVIIa in these and other types of patients, such as those with non-traumatic intracerebral hemorrhage^{3,4}, multiple injuries, prostatectomy⁵ and elective retropubic liver failure⁶.

The coagulopathy seen in patients with severe trauma develops according to the following causes: consumption of coagulation factors; hyper-fibrinolysis by activation of the fibrinolytic system; hypothermia which causes a slowing of enzymatic processes involved in coagulation, and dilutional coagulopathy

and platelet dysfunction caused by the infusion of large amounts of crystalloids, colloids and RBC concentrates without clotting factors and viable platelets. This results in impaired thrombin formation, so as soon as there are sufficient plasma levels of fibrinogen and prothrombin, the administration of rFVIIa may be beneficial and help generate thrombin in the amount necessary for the formation of a locally stable hemostatic clot⁷⁻⁹.

In 1999, Kennet et al.¹⁰ reported the successful use of rFVIIa in an injured soldier with massive bleeding, since when rFVIIa has gained popularity in the adjuvant management of coagulopathy, bleeding and acidosis associated with severe trauma. Many studies and clinical case series have attempted to substantiate its utility in trauma. Dutton et al.¹ reported a reversal of coagulopathy in 75% of patients treated, but no improvement in survival. Martinowitz and Michaelson¹¹ reported its use in 36 trauma patients and found significant differences in acidosis and bleeding, as well as clotting times, before and after administration. Kluger et al.¹² reviewed the literature on use of rFVIIa, and showed that its use achieved successful hemostasis without serious complications. The first controlled, randomized double-blind study on its use was published by Boffa in 2005¹³, showing that it dramatically and significantly decreased the need for RBC and massive transfusion.

In our case, the criteria for rFVIIa use were met: a patient with persistent massive bleeding who did not respond to available treatment and standard clinical measures. There is growing evidence that rFVIIa is a very useful tool in the treatment and control of massive bleeding; it should be considered in cases of bleeding that is difficult to control, such as multiple-injury patients. Both hospital and out-of-hospital Emergency Services are the first to attend and stabilize these patients, and if the degree of severity or complexity is high, extraordi-

nary measures may be required, including the use of rFVIIa. Therefore, we believe it should be available in such services and its use should be agreed on by consensus of the departments of Hematology, Anesthesia, Intensive Care and Pharmacy at each hospital.

References

- Dutton RP, McCunn M, Hyder M, D'Angelo M, O'Connor J, et al. Factor VIIa for correction of traumatic coagulopathy. *J Trauma*. 2004;57:709-19.
- Meng ZH, Wolberg AS, Monroe DM, Hoffman M. The effect of temperature and pH on the activity of factor VIIa. *J Trauma*. 2003;55:886-91.
- Mayer SA, Brun NC, Bergtrup K, Broderick J, Davis S, Dringer MN, et al, for the Recombinant Activated Factor VII Intracerebral Hemorrhage Trial Investigators. Recombinant activated factor VII for acute intracerebral hemorrhage. *N Engl J Med*. 2005;352:777-85.
- Spinella PC, Perkins JG, McLaughlin DF, Niles SE, Grathwohl KW, Beekley AC, et al. The effect of recombinant activated factor VII on mortality in combat-related casualties with severe trauma and massive transfusion. *J Trauma*. 2008;64:286-94.
- Friederich PW, Henny CP, Messenlink E, Geerdink MG, Keller T, Kurth KH, et al. Effect of recombinant activated factor VII on perioperative blood loss in patients undergoing retropubic prostatectomy: a double-blind placebo-controlled randomised trial. *Lancet*. 2003;361:201-5.
- Bosch J, Thabut D, Albillos A, Carbonell N, Spicak J, Hassard J, et al. Recombinant factor VIIa for variceal bleeding in patients with advanced cirrhosis: a randomized, controlled trial. *Hepatology*. 2008;5:1604-14.
- Hess JR, Brohi K, Dutton RP, Hauser CJ, Holcomb JB, Kluger Y, et al. The coagulopathy of trauma: a review of mechanisms. *J Trauma*. 2008;65:748-54.
- Parr MJ, Bouillon B, Brohi K, Dutton RP, Hanser CJ, Mess JR, et al. Traumatic coagulopathy: where are the good experimental models? *J Trauma*. 2008;65:766-71.
- Korte WC, Moor S. Near fatal hemorrhage in traumatic bilateral amputation with coagulopathy, acidosis, and hypothermia and salvage therapy with recombinant factor VIIa. *J Trauma*. 2007;63:E1-E4.
- Kenet G, Walden R, Eldad A, Martinowitz U. Treatment of traumatic bleeding with recombinant factor VIIa. *Lancet*. 1999;354:1879.
- Martinowitz U, Michaelson M. The Israeli Multidisciplinary rFVIIa Task Force. Guidelines for the use of recombinant activated factor VII (rFVIIa) in uncontrolled bleeding: a report by the Israeli Multidisciplinary rFVIIa Task Force. *J Thromb Haemost*. 2005;3:640-8.
- Kluger Y, Riou B, Rossaint R, Rizoli SB, Rossaint R, Warren B, et al. Safety of rFVIIa in hemodynamically unstable polytrauma patients with traumatic brain injury: post hoc analysis of 30 patients for a prospective, randomized, placebo-controlled, double-blind clinical trial. *Crit Care*. 2007;11:R85.
- Boffard KD, Riou B, Warren B, Choong P, Rizoli S, Rossaint R, et al. Recombinant factor VIIa as adjunctive therapy for bleeding control in severely injured trauma patients: two parallel randomized, placebo controlled, double blind clinical trials. *J Trauma*. 2005;59:8-18.

José Antonio FRANCO HERNÁNDEZ¹,
Rafael NIEBLES VELÁSQUEZ²,
Ignacio CUBIÁN GONZÁLEZ³,
Alejandra GARCÍA HERNÁNDEZ¹

¹Servicio de Anestesia y Reanimación. Hospital Universitario Miguel Servet, Zaragoza, Spain.

²Servicio de Anestesia y Reanimación del Hospital Militar Central de Bogotá, Colombia. ³Servicio de Urgencias del Centro Hospitalario San Millán-San Pedro. Logroño, Spain.

Urgent ultrasound in the diagnosis of esophageal perforation

Sir,

Esophageal perforation (EP) is a severe multi-factorial condition requiring emergency surgery and suc-

cessful outcome depends largely on early accurate diagnosis¹⁻³. In this regard, bedside ultrasound performed in the emergency department (ED) is a clear step forward, given its speed and discriminatory power⁴. We present a recent case that illustrates this.

A 49 year-old man with no medical history of interest was attended for dyspnea, retrosternal pain and sudden-onset left hemithorax, with pallor and sweating. Two days before he had had epigastric pain (sensation of "a knot in the stomach"), nausea and vomiting with traces of blood; he had refused the proposed gastroscopy and requested voluntary discharge. He was conscious, poorly perfused, with agitation, tachypnea, tachycardia, blood pressure 140/90 mmHg, scattered pulmonary rhonchi, and peripheral oxygen saturation of 88%. Urgent chest ultrasound revealed pleural sliding, stratosphere sign and lung point around the anterior axillary line, all suggestive of left pneumothorax, and pleural effusion (Figure 1). ECG showed sinus rhythm, 110 l / m and incomplete right bundle branch block. Chest x-ray showed pleural effusion and left basal infiltrate, without identifying pneumothorax. Computed tomography (CT) scan showed pneumothorax - accompanied by pneumomediastinum and left pleural effusion of atypical distribution, and despite no filter contrast from the esophagus, did not allow ruling out esophageal perforation - as well as atelectatic or pneumonia lung consolidation. Laboratory tests showed leukocytosis (20.900/mm³) with 75% neutrophils and hypoxemia (PaO₂ 48 mmHg with FiO₂ 0.5). A chest tube was placed at the 5th intercostal space, which drained serohematic content and food, and respiratory symptoms improved. With the initial diagnosis of EP, the patient was transferred to the chest surgery department, where perforation of the distal esophagus was found, along with a mediastinal

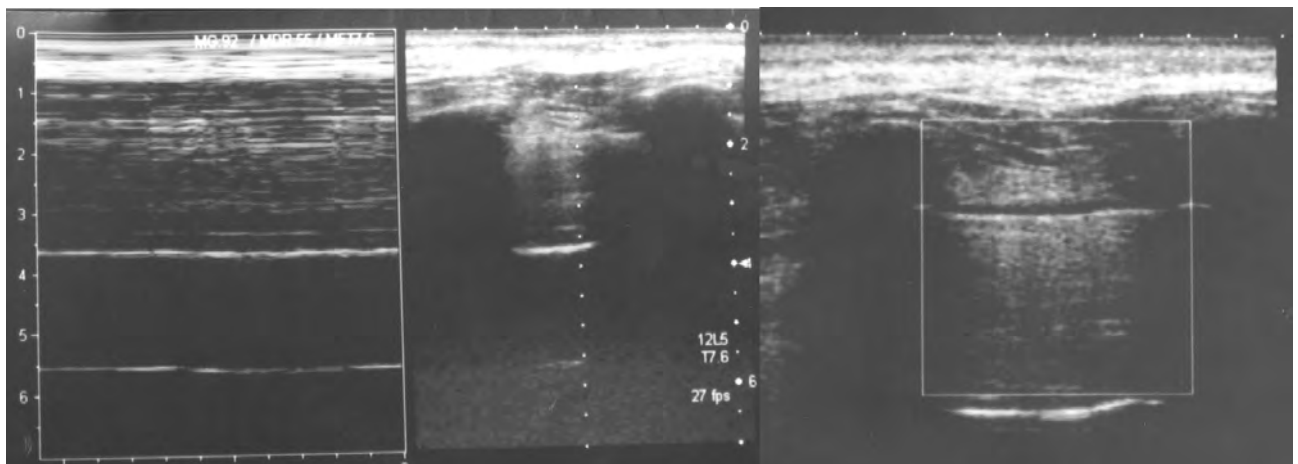


Figure 1. Chest ultrasound image showing no pleural sliding, suggestive of left pneumothorax.

abscess, successfully repaired. In the immediate postoperative period, he developed mediastinitis, septic shock and multiple organ failure; he was re-operated to repair the EP with gastric fundoplasty. Evolution progressed favorably until discharge.

The most frequent causes of EP are diagnostic procedures, trauma, and vomiting [Boerhaave syndrome (BS)]. The latter is essentially the result of a surge of intra-thoracic pressure, combined with negative pressure by vomiting, but the cause may also be caustic ingestion, drug-induced esophagitis, Barrett's esophagus and ulcers in patients taking NSAIDs¹⁻³. The tear is usually located in the posterolateral distal third. EP occurring outside the hospital environment, although less common, is associated with increased morbidity and mortality and delay in diagnosis, which favors the development of infectious complications (mediastinitis, mediastinal abscess or sepsis). Previous esophageal disease are not a pre-requisite for the development of EP, but contribute to increased mortality. The usual clinical history of BS includes nausea and vomiting, with severe retrosternal pain in the upper abdomen, and later symptoms may include sore throat, tachypnea, dyspnea, cyanosis, fever and shock³. The most common symptom is retrosternal chest pain which worsens with swallowing and breathing⁵. Physical examination is usually unhelpful initially. Subcutaneous emphysema is an important finding but lacks sensitivity, and pleural effusion or spontaneous pneumothorax may also be observed^{6,7}. Chest X-ray is abnormal in 80% of cases: mediastinal widening, subcutaneous emphysema or pleural effusion can take hours or days to develop.

CT scan usually shows edema and wall thickening, extra-esophageal air, peri-esophageal fluid with or without gas bubbles, mediastinum widening, air or fluid in pleural or retroperitoneal pleural spaces^{8,9}. Water-soluble contrast is mandatory in radiological studies to determine the location and size of EP. Endoscopy is not at all useful in EP and may even increase the tear and introduce air in the mediastinum. Ultrasound at the bedside is the most sensitive technique (signs of pleural sliding, stratosphere and lung point), and more specific than conventional chest X-ray for

the diagnosis of pneumothorax in critical patients^{6,7,10,11}.

EP is associated with high mortality (6-34%) and requires early treatment which depends on location, time to diagnosis and previous disease of the esophagus. Surgery should be performed early (first 24 h), and delay is related with increased mortality (30-50%), although current surgical techniques (Gastroplasty, as in this case, and coloplasty)¹² together with improved critical patient care have contributed to reducing mortality to 20%, even when primary surgical repair, mediastinal debridement and pleural drainage are deferred. Complications include persistence of the tear, mediastinitis and sepsis. Treatment also includes continuous nasogastric aspiration, antibiotics and parenteral nutrition.

ED physicians should be able to perform differential diagnosis with all the known causes of pneumothorax, pneumomediastinum and pleural effusion and, of course, cardiovascular diseases (ischemic heart disease, pulmonary thromboembolism, acute pericarditis or aortic syndrome) and infectious processes (pneumonia). Ultrasound - as the first imaging test and performed at the bedside - is a highly useful technique, already indicated in other urgent procedures^{4,13,14}, and can provide valuable diagnostic information from the outset^{6,7,10,11}. We would therefore recommend its early use in patients with chest pain and dyspnea suggestive of pneumothorax, even before forced exhalation chest X-ray.

References

- 1 Pate JW, Walker WA, Cole FH Jr, Owen EW, Johnson WH, et al. Spontaneous rupture of the esophagus: A 30-year experience. *Ann Thorac Surg.* 1989;47:689.
- 2 Brauer RB, Liebermann-Meffert D, Stein HJ, et al. Boerhaave's syndrome: Analysis of the literature and report of 18 new cases. *Dis Esophagus.* 1997;10:64-8.
- 3 McGovern M, Egerton MJ. Spontaneous perforation of the cervical esophagus. *Med J.* 1991;154:277.
- 4 Nogué R. La ecografía en Medicina de Urgencias: una herramienta al alcance de los urgenciólogos. *Emergencias.* 2008;20:75-7.
- 5 Kundra M, Yousaf S, Maqbool S, Mahajan PV. Boerhaave syndrome-unusual cause of chest pain. *Pediatr Emerg Care.* 2007;23:489-91.
- 6 Lichtenstein DA, Menu Y. A bedside ultrasound sign ruling out pneumothorax in the critically ill. *Lung sliding.* *Chest.* 1995;108:1345-8.
- 7 Lichtenstein DA, Mezière G, Lascols N, Biderman P, Courret JP, Gepner A, et al. Ultrasound diagnosis of occult pneumothorax. *Crit Care Med.* 2005;33:1231-8.
- 8 De Lutio di Castelguidone E, Merola, S, Pinto, A, Raissaki M, Gagliardi W, Romano L. Esophageal injuries: spectrum of multidetector row CT findings. *Eur J Radiol.* 2006;59:344-8.
- 9 Backer, CL, Lo Cicero, J 3d, Hartz, RS. Computed tomography in patients with esophageal perforation. *Chest.* 1990;98:1078.
- 10 Lichtenstein D, Mezière G, Biderman P, Gepner A. The comet-tail artifact: an ultrasound sign ruling out pneumothorax. *Intensive Care Med.* 1999;25:383-8.
- 11 Lichtenstein D, Mezière G, Biderman P, Gepner A. The "lung point": an ultrasound sign specific to pneumothorax. *Intensive Care Med.* 2000;26:1434-40.
- 12 Farrán L, Miró M, Biondo S. Reconstrucción esofágica en un segundo tiempo: coloplastia y gastroplastia. *Cir Esp.* 2008;83:242-6.
- 13 Pintado R, Moya M, Sánchez S, Castro MA, Plaza S, Mendo M. Indicación y utilidad de la ecografía urgente en la sospecha de apendicitis aguda. *Emergencias.* 2008;20:81-6.
- 14 García LA, Campo R, Rayo M. Pericarditis purulenta: diagnóstico ecográfico precoz en el Servicio de Urgencias. *Emergencias.* 2008;20:135-8.

Ricardo CAMPO LINARES¹,
Emilio MORENO MILLÁN²,
Francisca PRIETO VALDERREY²,
Manuel CASTARNADO CALVO¹

¹Servicio de Urgencias. ²Servicio de Medicina Intensiva. Hospital Santa Bárbara, Puertollano. Ciudad Real, Spain.

Spontaneous hemoperitoneum due to rupture of an umbilical vein varix

Sir,

Spontaneous rupture of an intra-abdominal varix is a rare complication and unusual cause of hemoperitoneum. Prognosis is poor, with a mortality that exceeds 75%^{1,2}. Liver cirrhosis is the most common cause of portal hypertension and ascites, and is associated with the development of extensive collateral circulation^{3,4}. This redistribution of abdominal blood flow causes the appearance varices that may rupture and lead to serious bleeding⁵.

A 73 year-old patient with a history of chronic liver disease attended the emergency department (ED) for syncope and diffuse abdominal pain, without signs of peritoneal irritation. Laboratory tests showed hematocrit 25.2% and prothrombin activity 51%. With suspected acute arterial vascular disease, thoracoabdominal computed tomography (CT) scan of the liver showed chronic hepatopathy with signs of chronic portal hypertension, a markedly dilated umbilical vein and

abundant free fluid suggestive of asciti-coedematous decompensation against hemoperitoneum, without a demonstrable bleeding point (Figure 1). Urgent angiography was inconclusive, but exploratory laparotomy confirmed the presence of massive hemoperitoneum from the umbilical vein. Postoperatively, the patient died from hepatorenal syndrome.

The causes of hemoperitoneum in patients with a history of liver disease can be either iatrogenic or spontaneous varix rupture¹. It can manifest as hemorrhagic shock or, more usually, as clinical worsening of the liver disease accompanied by increased abdominal girth^{3,4}. Spontaneous rupture of intra-abdominal varices is a rare complication in patients with portal hypertension and an uncommon cause of hemoperitoneum⁵. We should think about this complication when abdominal pain, with or without bloating, is associated with hypotension in a patient with a history of portal hypertension secondary to liver cirrhosis.

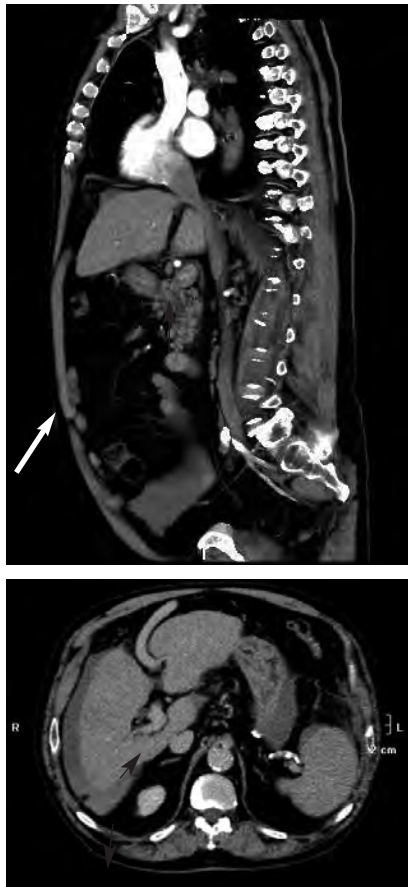


Figure 1. Thoracoabdominal CT scan showing a dilated umbilical varicose vein (arrow).

References

- 1 Vallalta M, Cano B, Morata A, Calabuig A. Hemoperitoneo secundario a la rotura espontánea de la vena umbilical. *Gastroenterol Hepatol.* 2004;27:414-6.
- 2 Kosowsky JM, Gibler WB. Massive hemoperitoneum due to rupture of a retroperitoneal varix. *J Emerg Med.* 2000;19:347-9.
- 3 Leaute F, Frampas E, Mathon G, Leborgne J, Dupas B. Massive hemoperitoneum from rupture of an intra-peritoneum varix. *J Radiol.* 2002;83:1775-7.
- 4 Moreno JP, Pina R, Rodríguez F, Korn O. Spontaneous hemoperitoneum caused by intraabdominal variceal rupture in a patient with liver cirrhosis. Clinical case. *Rev Med Chil.* 2002;130:433-6.
- 5 Chu EC, Chick W, Hillebrand DJ, Hu KQ. Fatal spontaneous gallbladder variceal bleeding in a patient with alcoholic cirrhosis. *Dig Dis Sci.* 2002;47:2682-5.

José Antonio FRANCO HERNÁNDEZ¹,
Amós URTUBIA PALACIOS¹,
Luis Manuel CLARACO VEGA¹,
José María ARTIGAS MARTÍN²

¹Servicio de Urgencias. ²Servicio de Radiodiagnóstico. Hospital Universitario Miguel Servet. Zaragoza, Spain.

Unexplained paraparesis after a recent spinal anesthetic

Sir,

Neurological deficit after spinal cord anesthesia is rare¹. Its appearance after neuraxial anesthesia requires ruling out previous spinal cord syndrome, epidural hematoma, abscess, arachnoiditis, infections, medical and neurological toxic-metabolic diseases and other infrequent causes. Early diagnosis favors better prognosis.

A 37 year-old woman attended the emergency department complaining of heaviness of legs, dysesthesia and pain. The patient had undergone was hernia surgery 19 hours before, under lumbar anesthesia with a Whitaker 27G needle and 3 ml of 3% lidocaine. On physical examination she was afebrile, 3-4/5 paraparesis with sensory impairment at D11-D12, tenderness to touch, pressure and temperature with anarchic delimitation. She showed no sphincter alteration and muscle tone of the lower limbs was preserved with normal deep tendon reflexes. Laboratory tests, chest X-ray, electromyography and MRI were normal. After ruling out organic causes, she was diagnosed by a psychiatrist with mixed conversion disorder and treated psychologically. Finally, she recovered baseline physical condition after several sessions.

Severe neurological complications after regional anesthesia are rare

(0.005 to 0.7%)^{2,3} and can be caused by many factors^{4,5}. The most common causes of neurological complications include neurotoxicity to local anesthetic and needle-induced trauma. Numerous publications blame the local anesthetic used, by direct neurotoxicity, especially the use of hyperbaric lidocaine 5%^{7,8}. In our patient, after recovery from sensory and motor blockade, there were neurological symptoms. She did not receive large volumes of lidocaine or repeated injections, and the solution was preservative-free.

There were no episodes of inter or postoperative hypotension, and vasoconstrictor agents were not used. These are all known factors that may contribute to spinal ischemic damage.

Conversion disorders are included in sematoform disorders. Prevalence rate is 11-30/100.000. The essential characteristic is the presence of deficit that affects motor or sensory function suggesting a medical condition, but can not be explained by organic causes, drugs or behavior^{9,10}. The symptoms are often inconsistent, short-term and recur regularly, but not intentionally. Diagnosis of conversion disorder should be provisional and tentative, because it sometimes requires multiple studies and years to rule out or find organic pathology underlying the disorder.

References

- 1 Chhibber AK, Lustik SJ. Unexpected neurologic deficit following spinal anesthesia. *Reg Anesth.* 1996;21:355-7.
- 2 Auroy Y, Narchi P, Messiah A, Litt L, Rouvier B, Samii K. Serious complications related to regional anesthesia: results of a prospective survey in France. *Anesthesiology.* 1997;87:479-86.
- 3 Horlocker TT, McGregor DG, Matsushige DK, Schroeder DR, Besse JA. A retrospective review of 4767 consecutive spinal anesthetics: central nervous system complications. Perioperative Outcomes Group. *Anesth Analg.* 1997;84:578-84.
- 4 Malinovsky JM, Pinaud M. Neurotoxicité des agents administrés par voie intrathécale. *Ann Fr Anesth Réanim.* 1996;15:647-58.
- 5 López-Soriano F, Lajarín B, Verdú JM, Rivas F, López-Robles J. Hemisíndrome de cauda equina tras anestesia intradural con bupivacaína para cirugía de cadera. *Rev Esp Anestesiología Reanim.* 2002;49:494-6.
- 6 Horlocker TT. Neurologic complications of neuroaxial and peripheral blockade. *Can J Anesth.* 2001;48:R1-R8.
- 7 Kanai Y, Katsuki H, Takasaki M. Lidocaine disrupts neuronal membrane of rat sciatic nerve in vitro. *Anesth Analg.* 2000;91:944-8.
- 8 Saludes J, Masip R, Sala P, Gómez E, Rull M. Cuadro doloroso en las extremidades inferiores después de bloqueo subaracnoideo con

lidocaína. Rev Esp Anesthesiol Reanim. 1996;43:330-2.

9 Orr DL, Glassman AS. Conversion phenomenon following general anesthesia. J Oral Maxillofac Surg. 1985;43:817-9.

10 Blinder D, Rotemberg L, Taicher S. Conversion disorder after maxillofacial trauma and surgery. Int J Oral Maxillofac Surg 1996;25:116-8.

Manuel CORTIÑAS SAÉNIZ¹,
David CALDEVILLA BERNARDO²,
María Luz CORTIÑAS SAÉNIZ³,
Josefa MARTÍNEZ PÉREZ²

¹Servicio de Anestesiología y Reanimación. Hospital Torrecárdenas. Almería, Spain. ²Servicio de Urgencias. Complejo Hospitalario Universitario. Albacete, Spain. ³Servicio de Análisis Clínicos. Hospital Virgen de la Salud. Granada, Spain.

Post-traumatic neurapraxia in Klippel-Feil syndrome

Sir,

Klippel-Feil syndrome (KFS) has a series of heterogeneous manifestations but the key criterion is congenital fusion of two or more cervical vertebrae¹. Approximately 68% of patients have neurological symptoms, especially in adults², including chronic neck pain, with marrow or radicular compression, gross spinal deformity or acute myelopathy due to increased risk of traumatic neck injury^{1,3}.

A 38 year-old patient was attended for cervical whiplash causing pain and paresthesia in the ulnar territory of both arms. Radiography showed congenital C5-C6 cervical block, without fracture or dislocation. With suspected spinal cord injury, the patient received the NASCIS II protocol (methylprednisolone) and urgent magnetic resonance imaging (MRI) which confirmed the cervical block and showed scoliosis and degenerative changes in the disc immediately above the block, with a slight reduction in the central canal of the spinal cord. There were no areas with contusive bleeding or significant foraminal stenosis (Figure 1). Although pain and paresthesia increased during the first 24 hours, this was followed by progressive improvement, with complete resolution of symptoms and hospital discharge seven days later.

KFS patients, especially those with canal stenosis, are at high risk of spinal injury after minor trauma, manifesting transient and often recurrent symptoms, or even severe tetraplegia or fatal subluxation^{1,4}. The cause is attributed to lack of mobility of the fused segment, compensated by hypermobility of adjacent segments. This alteration or transfer of

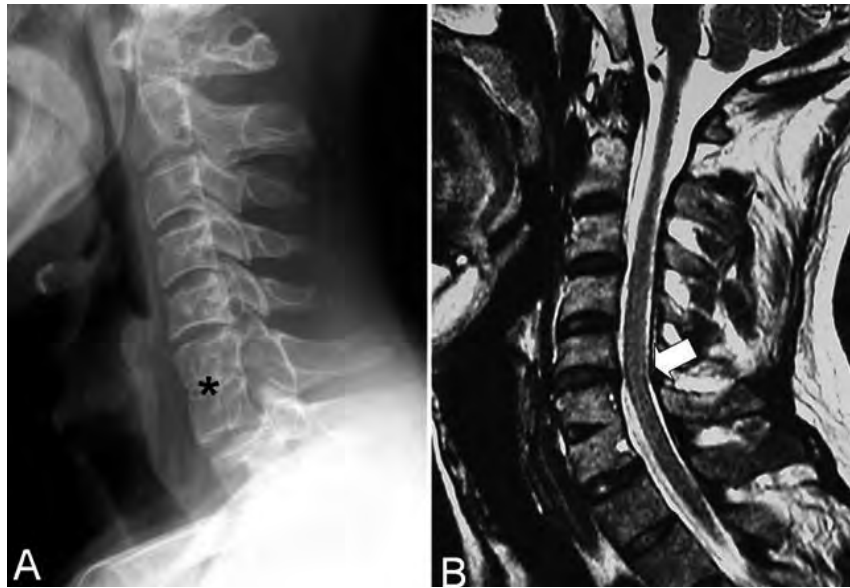


Figure 1. A) lateral cervical spine radiograph showing a correction of physiological cervical lordosis and congenital C6-C7 vertebral fusion (asterisk). The fusion is observed in both the cell bodies and the posterior elements, and the narrowing of the central somatic block at the level of theoretical disc space, as often happens in congenital fusion. B) MRI, fast spin-echo (FSE) T2 sagittal sequence. Spinal signal is virtually normal, with slight ill-defined enhancement of the spinal cord signal, but without contusive points. Degenerative disc phenomena immediately above the cervical block slightly constrict the central canal and obliterate the subarachnoid space (arrow).

power in the cervical region causes overload on the unfused segments that favors early degenerative changes in the discs and apophyseal joints, with the risk of foraminal and central canal stenosis.

In our patient, the distal arm hyperesthesia is characteristic of burning hand syndrome or glove paresthesia⁵⁻⁷. Paresthesia with evidence of tenderness and reflex preservation is more suggestive of myelopathy than peripheral neuropathy. In these cases, when EMG and nerve conduction tests are normal, it is very useful to include somato-sensorial evoked potentials in the evaluation⁶. KFS can be considered the mildest form of traumatic central cord syndrome, which is unusual but usually has good prognosis with complete or almost complete recovery within 72 hours⁷. Its pathogenesis is not entirely clear. Maroon et al.⁶ have suggested that symptoms may be due to irritation of the spinothalamic bundle in the anterolateral quadrant of the spine, affecting the nerve fibers responsible the perception of pain. MRI may be normal or nearly normal with a very discrete hyper-signal due to edema of the spinal cord⁸.

There is some controversy regarding the indication of arthrodesis in KFS. Some authors recommended

this in cases of excessive hypermobility⁹, while others recommend it in cases of acute or progressive symptoms or in asymptomatic patients with a history of transient injuries¹⁰.

KFS patients, especially those with a narrow central spinal canal, must be informed of their potential risk of neurological injury, in order to modify physical behavior related with sporting and occupational activities¹.

References

- Vaidyanathan S, Hughes PL, Soni BM, Singh G, Sett P. Klippel-Feil syndrome - the risk of cervical spinal cord injury: A case report. BMC. Fam Pract. 2002;11:3-6.
- Samartzis D, Herman J, Lubicky JP, Shen FH. Classification of congenitally fused cervical patterns in Klippel-Feil patients. Spine. 2006;31:E798-804.
- Ulmer JL, Elster AD, Ginsberg LE, Williams DW. Klippel-Feil syndrome: CT and MR of acquired and congenital abnormalities of cervical spine and cord. J Comput Assist Tomogr. 1993;17:215-24.
- Matsumoto K, Wakahara K, Sumi H, Shimizu K. Central cord syndrome in patients with Klippel-Feil syndrome resulting from winter sports. Am J Sports Med. 2006;34:1685-9.
- Maroon JC. Burning hand in football spinal cord injuries. JAMA. 1977;238:2049-51.
- Smith T, Trojaborg W. Somatosensory evoked potentials in the evaluation of patients with stocking/glove paresthesias. Acta Neurol Scand. 1989;79:63-7.
- Wilberger JE, Abia A, Maroon JC. Burning

- hands syndrome revisited. *Neurosurgery*. 1986;19:1038-40.
- 8 Saifuddin A. MRI of acute spinal trauma. *Skeletal Radiology*. 2001;30:237-46.
- 9 Nagib MG, Maxwell RF, Chou SN. Identification and management of high-risk patients with Klippel-Feil syndrome. *J Neurosurg*. 1984;61:523-30.
- 10 Nagashima H, Morio Y, Teshima R. No Neurological involvement for more than 40 years in Klippel-Feil syndrome with severe hypermobility of the upper cervical spine. *Arch Orthop Trauma Surg*. 2001;121:99-101.

Esteban MAYAYO SINUÉS¹,
 Antonia Pilar SORIANO GUILLÉN²,
 Elena ANGULO HERVÍAS¹,
 Magdalena COZAR BARTOS¹

¹Servicio de Radiodiagnóstico. ²Servicio de Urgencias. Hospital Universitario Miguel Servet. Zaragoza, Spain.

Spontaneous hemopneumothorax

Sir,

Spontaneous hemopneumothorax is an uncommon condition found in 1-12% of patients with spontaneous pneumothorax¹. It is predominantly observed in adolescents and young adults; if accompanied by significant bleeding, it may result in shock in 30% of cases² and, finally, death if early chest drainage is not performed. The cause is usually rupture of vascularized pleuropulmonary bullae or adhesions³.

A 26 year-old woman with no medical history of interest, allergic to penicillin, attended the emergency department for right upper chest pain and dyspnea. Posteroanterior and lateral chest radiography revealed right pneumothorax and hydrothorax (Figure 1). Blood test showed hemoglobin 9.8 g / L and hematocrit 31%. The patient suddenly presented syncope with loss of consciousness, hypotension and cardiorespiratory arrest. Cardiopulmonary resuscitation was initiated and a 20F chest tube was placed at the right 5th

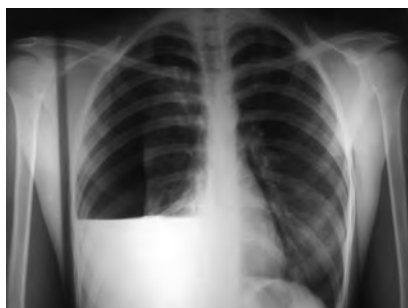

Figure 1. Hemopneumothorax. Posteroanterior chest X-ray.

intercostal space, with rapid recovery of cardiorespiratory function and vital constants. The drain collected 700 cc of blood and air. Patient evolution was favorable.

Spontaneous hemopneumothorax may rapidly lead to life-threatening complications, so early chest drainage must be performed on arrival at the ED, especially if the patient is unstable. In stable patients in a hospital environment with thoracic surgery available, video-assisted thoracic surgery is considered the treatment of choice⁴.

References

- Kakar S, Athanassiadi K, Vassilos K, Skottis I. Spontaneous hemopneumothorax: a rare but life-threatening entity. *Eur J Cardiothorac Surg*. 2004;25:856-8.
- Hsu NY, Shih CS, Hsu CP, Chen PR. Spontaneous hemopneumothorax revisited: clinical approach and systemic review of the literature. *Ann Thorac Surg*. 2005;80:1859-63.
- Issaivanan M, Baranwal P, Abrol S, Bajwa G, Baldauf M, Shukla M. Spontaneous hemopneumothorax in children: case report and review of literature. *Pediatrics*. 2006;118:1268-70.
- Cardillo G, Facciolo F, Giunti R, Gasparri R, Lopercolo M, Orsetti R, et al. Videothoracoscopic treatment of primary spontaneous pneumothorax: a 6-year experience. *Ann Thorac Surg*. 2000;69:357-61.

José Daniel LACASTA GARCÍA,
 Cecilia LLOBET PINA

Servicio de Urgencias. Hospital Universitario Arnau de Vilanova. Lleida, Spain.

Pneumobilia as a sign of bile duct disease

Sir,

Pneumobilia or aerobilia is sometimes an incidental finding but in any event indicates the presence of bile duct disease¹ which may range in severity from mild to severe and require immediate attention. We present the case of a patient with persistent fever of initially unknown origin. One of the ED tests performed allowed us to detect aerobilia and identify the focal cause of the fever.

A 78 year-old man with diabetes and hypertension was attended in our ED for dyspnea and leg edema, dry cough and fever 37.7 °C during five days. Physical examination showed blood pressure of 99/45 mmHg, heart rate 100 bpm, and O₂ saturation 94% with FiO₂ 0.26. He was afebrile. We found right hypochondriac pain with negative Murphy's sign.

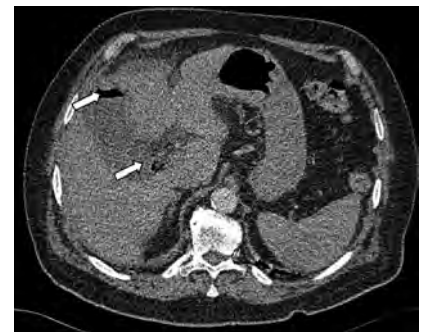


Figure 1. Computed tomography angiography showing gas in the biliary tree (arrows).

Laboratory tests showed: creatinine 1.8 mg / dL, leukocytosis 13.980/μL (total neutrophils 12,160/μL) and D-dimer 809 ng / mL. Chest radiography showed elevated right hemidiaphragm with left laminar atelectasis. Arterial blood gasometry showed hypoxemic hypocapnic hypoxemia. With these findings and the absence of appreciable condensation, angiography was requested and this allowed ruling out pulmonary embolism but revealed the presence of gas in the biliary tract (pneumobilia) (Figure 1) and an image compatible with right basal condensation. The patient was treated empirically with amoxicillin-clavulanate. Liver profile showed total bilirubin of 3.4 mg / dL. Evolution in the ED was poor with hemodynamic and clinical worsening. With a new diagnosis of fever due to biliary causes, and after consulting the hospital surgery department, cholecystectomy was performed. Pathologically, the specimen removed showed the presence of vesicular empyema due to Enterobacter infection.

The presence of air in the biliary tree may signal either a benign disease (primarily iatrogenic) or a severe life-threatening condition². Pneumobilia occurs as a complication of acute cholecystitis in 15% of cases³, often indicating the presence of an enterobiliary fistula⁵, which may also be caused by duodenal diverticulosis⁶. In our case, the diagnosis of cholecystitis was delayed given the latent presentation and the absence of clear signs for the diagnosis. It was the presence of pneumobilia that provided a guide to the final diagnosis.

References

- Vialle R, L'helgouarc'h JL, Burdy G, Mellot F, Attal E, Frileux P. Aerobilia: a rare consequence of anaerobic acute cholecystitis: a case report. *Gastroenterol Clin Biol*. 2002;26:289-91.
- Browning LE, Taylor JD, Clark SK, Karanjia

- ND. Jejunal perforation in gallstone ileus - a case series. *J Med Case Reports*. 2007;1:157.
- 3 Isch JH, Finneran JC, Nahrwald DL. Perforation of the gallbladder. *Am J Gastroenterol*. 1971;55:451.
- 4 Schiemann U, Dayyani V, Müller-Lisse UG, Siebeck M. Aerobilia as an initial sign of a cholecystoduodenal fistula--a case report. *MMW Fortschr Med*. 2004;146:39-40.
- 5 Inal M, Oguz M, Aksungur E, Soyupak S, Börüban S, Akgül E. Biliary-enteric fistulas: report of five cases and review of the literature. *Eur Radiol*. 1999;9:1145-51.
- 6 Arredondo A. Algoritmo para el diagnóstico de la fístula bilio-entérica. *Revista de Especialidades Médico Quirúrgicas*. 2008;13:139-42.

Marta TRENCHS RODRÍGUEZ,
José Luis ECHARTE PAZOS,
María Jesús LÓPEZ CASANOVA

Servicio de Urgencias. Hospital Universitario del Mar. Barcelona, Spain.

Pneumococcal peritonitis in a patient without previous symptoms

Sir,

Peritonitis is one of several extrapulmonary infections produced by pneumococcus^{1,2}. We present a case of intra-abdominal infection by pneumococcus that evolved with singular clinical characteristics.

A 46 year-old Bolivian woman resident in Spain for two years, working in domestic service, with no medical history of interest, attended the emergency department with fever 39.5 °C, shivering and epigastric pain radiating to both hypochondria during 24 hours. Physical examination showed board-like abdominal rigidity and upper abdominal tenderness on palpation. Laboratory tests showed leukocytes 4,100/ mL (36% band cells) with hematocrit 31%. Standing abdominal radiography showed hydroaerial levels. After blood cultures, urgent laparotomy showed purulent free fluid and some serositis, but no visceral continuity defect or other sites of abdominal infection. The patient was treated with intravenous imipenem 500 mg/6 h. In the four blood cultures obtained before surgery and in the peritoneal fluid culture, penicillin-resistant *Streptococcus pneumoniae* was isolated. This finding prompted a change in antibiotic therapy, to intravenous ceftiraxone 1 g/24 h administered during 14 days. HIV serology was negative. Pelvic examination with ultrasound was normal. Vaginal culture showed normal flora. Additional tests (abdominal ultrasound, echocardiogram, and isotopic tracing with gallium) were also normal. At the time of discharge, the patient was asymptomatic.

Pneumococcus is a pathogen which may cause primary peritonitis

in patients with liver disease, chronic nephrotic syndrome and other diseases with peritoneal involvement^{3,5}, and sometimes as a complication of pneumonia³. Secondary peritonitis caused by perforation of hollow viscera have also been described². The patient did not suffer any pathology associated with primary peritonitis, or hollow viscera perforation, similar to other cases of women who present with evident acute abdomen sometimes mimicking acute appendicitis², whose origin is ascending infection after pneumococcal colonization of the vagina^{6,7}. Some of these cases have appeared in maturing girls, especially in developing countries, in women with intrauterine devices and in women with HIV infection^{4,6-8}. Vaginal colonization may occur by extension from the digestive tract, from the respiratory tract transmitted by the hands, by oral-genital contact or by hematogenous contact^{9,10}.

In one third of these cases there is bacteremia³. With surgical treatment and an appropriate antibiotic, vital prognosis is usually favorable⁸.

References

- 1 Debbia EA, Schito GC, Zoratti A, Gualco L, Tonoli E, Marchese A. Epidemiology of major respiratory pathogens. *J Chemother*. 2001;13:205-10.
- 2 Nielsen KR, Ejlersten T, El-Batran S, Prag J. A five-year survey of pneumococcal peritonitis in two Danish counties--incidence, diagnosis and clinical entities. *J Clin Microbiol Infect*. 2003;9:738-40.
- 3 Hemsley C, Eykyn SJ. Pneumococcal peritonitis in previously healthy adults: case report and review. *Clin Infect Dis*. 1998;27:376-9.
- 4 Capdevila O, Pallares R, Grau I, Tubau F, Liñares J, Ariza J, et al. Pneumococcal peritonitis in adult patients: report of 64 cases with special reference to emergence of antibiotic resistance. *Arch Intern Med*. 2001;161:1742-8.
- 5 Dugi DD, Musher DM, Clarridge JE, Kimbrough R. Intraabdominal infection due to *Streptococcus pneumoniae*. *Medicine (Baltimore)*. 2001;80:236-44.
- 6 Alifrangis C, Thompson P, Thwaites G, Churchill D. Primary pneumococcal peritonitis as a presenting feature of HIV infection. *Int J STD AIDS*. 2006;17:779-80.
- 7 Rudensky B, Abramowitz H, Yinnon AM, Alberton J. Intrauterine device as source of pneumococcal intra-abdominal infection and small-bowel obstruction. *Eur J Clin Microbiol Infect Dis*. 2004;23:576-7.
- 8 Muñoz-Morente A, Grana-Costa M, Palacios-Rodríguez S, Castillo-Caballero JM. Peritonitis bacteriana espontánea en una paciente con un dispositivo intrauterino. *Enferm Infecc Microbiol Clin*. 2007;25:163-4.
- 9 Bucher A, Müller F. Spectrum of abdominal and pelvic infections caused by pneumococci in previously healthy adult women. *Eur J Clin Microbiol Infect Dis*. 2002;21:474-7.
- 10 Garnache F, Simon M, Goffinet P. Péritonites primitives à *Streptococcus pneumoniae*. *J Gynecol Obstet Biol Reprod*. 1997;26:617-22.

Antonio RAMOS MARTÍNEZ¹,
Juan GONZÁLEZ GONZÁLEZ²,
Manuel GIL NAVARRO¹,
Isabel SÁNCHEZ ROMERO³

¹Unidad de Infecciosas. Servicio de Medicina Interna. ²Servicio de Cirugía General. ³Servicio de Microbiología. Hospital Universitario Puerta de Hierro. Universidad Autónoma de Madrid, Spain.

Severe respiratory failure secondary to enalapril angioedema

Sir,

Angiotensin converting enzyme inhibitors (ACEI) are widely used, and among the side effects described is the development of angioedema. We present the case of a patient who developed upper respiratory failure secondary to severe oral cavity and tongue edema that coincided with the use of enalapril; a complication of such intensity has rarely been described in the literature¹.

A 41 year-old patient 41, with no history of allergy (to drugs or other substances) was diagnosed with hypertension and treated with oral enalapril (5 mg/24 h). Twenty-four hours later he attended the ED for edema of the right side of the tongue. He was treated with 60 mg intramuscular methylprednisolone and discharged home. Within a few hours he was readmitted for generalized edema of the tongue, accompanied by speech difficulty. Fibroscopy showed edema of the oral cavity and oropharynx (larynx and hypopharynx normal), and he was transferred to the intensive care unit (ICU) for surveillance. On admission he was hypertensive (BP 200/110 mmHg), with respiratory distress, but laboratory tests showed no abnormalities. Breathing difficulty soon increased with obstructive upper respiratory symptoms, swollen lips and throat. Precautionary endotracheal intubation was unsuccessfully attempted due to the edema and then emergency cricothyroidotomy, was performed to re-establish ventilation. He was treated with iv. maleate dexchlorpheniramine 5mg/6 h and iv. methylprednisolone 125 mg/6 h, resulting in significant decrease of the oropharyngeal edema. He was transferred to a hospital ward three days later, and discharged home two days later. During hospitalization, the following tests were performed: immunoglobulin, complement, C1-inhibitor complement, thyroid hormones, ANA antibodies, viral serology, and all were normal. Other possible allergens were ruled out by the laboratory

tests and the temporal relation with no other substance except enalapril.

The first description of ACEI-induced angioedema dates back to 1984, with a frequency ranging from 0.1-0.2%², and overall incidence in the S.O.L.V.D study was 5/1,000 in the group treated with enalapril³. This seems to be higher during the first week of treatment⁴, and can occur even years after receiving the drug; its appearance is unrelated to dose administered. Risk factors have been associated described, including black race, narrowness of the oropharynx, obesity, surgery or previous trauma to the head or neck.

The underlying cause is not IgE-mediated and seems more like a pharmacological effect⁵. It may be due to increased levels of bradykinin on decreasing catabolism by decreased ACEI causing leakage of fluid into the interstitial space and edema⁴. Another possibility is that the passage of angiotensin II is blocked, causing vasodilation and potentiating the edema⁶.

Clinical manifestations vary from swelling of the face, edema of the tongue and supraglottic area (tongue and lips most frequently⁷) to the rarely reported edema of the hands, feet and abdominal viscera. Symptoms are usually mild and self-limiting, and disappear after with-

drawal of the medication. The differential diagnosis includes infections of the upper respiratory tract or dental, epiglottitis, asthma and anaphylaxis. While there are few reports of obstructive upper respiratory distress, as in our case, this can develop to complete obstruction of the airway and cause death¹. This occurs more frequently when the edema affects the floor of the mouth, base of the tongue and oropharynx, and is less serious when located in the face and oral cavity.

Regarding treatment, the cornerstones are drug withdrawal (usually resulting in symptom reversal within hours), airway management and seeking evident causes of respiratory compromise (stridor, tongue edema, dyspnea, dysphagia and increased salivation). Antihistamines and corticosteroids can be used, but their utility has not been demonstrated in ACEI-induced angioedema.

Given the increasing use of ACEI drugs, we could face an emerging complication that must be considered in patients attending the ED with a picture of upper respiratory difficulties due to edema⁸.

References

- 1 Dean D, Schultz DL, Powers RH. Asphyxia due to angiotensin converting enzyme (ACE) inhibitor mediated angioedema of the tongue during the treatment of hypertensive heart disease. *J Forensic Sci.* 2001;46:1239-43.
- 2 Sondhi D, Lippman M, Murali G. Airway Compromise Due to angiotensin-Converting Enzyme Inhibitor-Induced Angioedema: Clinical Experience at a Large Community Teaching Hospital. *Chest.* 2004;126:400-4.
- 3 Kostis JB, Shelton B, Gosselin G. Adverse effects of enalapril in the Studies of Left Ventricular Dysfunction. *Am Heart J.* 1996;131:350-5.
- 4 Israili ZH, Hall WD. Cough and angioneurotic edema associated with angiotensin-converting enzyme inhibitor therapy. A review of the literature and pathophysiology. *Ann Intern Med.* 1992;117:234-42.
- 5 García Dumpierrez A, Almeida L, Blanco C, Castillo R, Ortega N, Carrillo T. Angioedema por inhibidores de la enzima de conversión de la angiotensina (IECA). *Alergol Immunol Clin.* 2000;15:396-9.
- 6 Sabroe RA, Black AK. Angiotensin-converting enzyme (ACE) inhibitors and angio-edema. *Br J Dermatol.* 1997;136:153-8.
- 7 Agah R, Bandi V, Guntupalli KK. Angioedema: the role of ACE inhibitors and factors associated with poor clinical outcome. *Intensive Care Med.* 1997;23:793-6.
- 8 Banerji A, Clark S, Blanda M, LoVecchio F, Snyder B, Camargo CA. Multicenter study of patients with angiotensin-converting enzyme inhibitor-induced angioedema who present to the emergency department. *Ann Allergy Asthma Immunol.* 2008;100(4):327-32.

Alberto CORDOBA LÓPEZ,
David GRANADO MARTÍNEZ,
María Dolores PÉREZ FRUTOS,
Baldomero JIMENO TORRES

Unidad de Cuidados Intensivos. Hospital Perpetuo Socorro. Complejo Hospitalario Universitario de Badajoz. Spain.