
IMAGES

On football fans and sports-related risk

SERGIO NAVARRO GUTIÉRREZ, JULIÁN A. MOLINA JAIME, ELADIO LAPRESA ACOSTA

Servicio de Urgencias. Hospital de Torrevieja. Área 22. Agencia Valenciana de Salud. Alicante, Spain.

A 33 year-old man arrived at the emergency department by his own means with a screwdriver shaft protruding about 3cm from the region of the left superciliary arch. He had been assaulted while watching a football match. In the initial physical examination he showed discrete tachypnea and mucocutaneous pallor. There were no neurological focal signs whatsoever, and the patient only reported mild spontaneous pain in the area of insertion but no visual impairment.

Cranial computed tomography (CT) scan (Figure 1) showed a metal object penetrating the left frontal region, in the anterior cranial fossa, directly above the orbit, through the posterior orbital roof and passing diagonally across the body of retrobulbar fat (the optic nerve seemed to be unharmed but damage to the medial rectus muscle could not be ruled out), crossed the lamina

papyracea and isolated ethmoid cells and ended at the sphenoid sinus floor. We did not observe any significant bleeding, fluid collection or pneumoencephalus. In the medial area of the shaft we observed a slightly hyperdense subcalotal-frontal-basal area measuring 0.4 x 1.8 cm, suspected to be a small sub- or epidural hematoma. The brain structures and eyeball appeared undamaged, and the remaining surrounding structures were normal.

The patient was transferred to a neurosurgical referral hospital where elliptical craniotomy was performed, and the shaft was extracted by traction. The orifice was plugged with bone wax, and the bone replaced and sealed with 3 plates. After a CT scan and assessment by an ophthalmologist and otolaryngologist, the patient was discharged home.

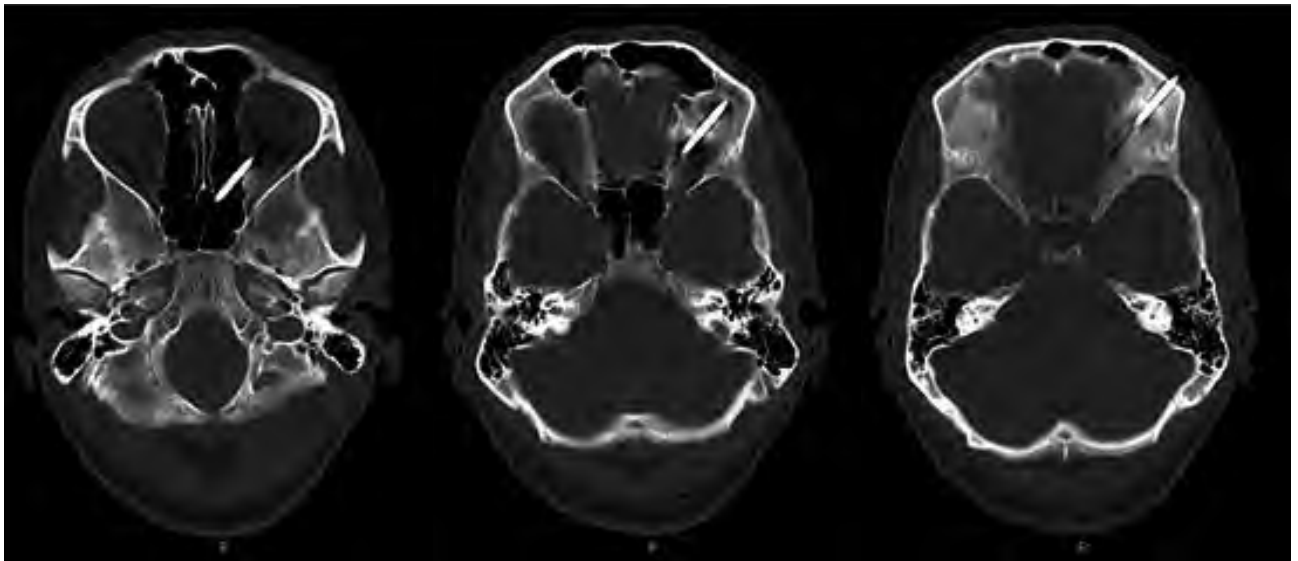


Figure 1. Sequential cranial CT slices showing the trajectory of the screwdriver shaft.

CORRESPONDENCE: Sergio Navarro Gutiérrez. C/Guillem de Castro, 29, 5°. 46007 Valencia, Spain.

E-mail: sergionavarrog@hotmail.com.

RECEIVED: 8-5-2008. **ACCEPTED:** 15-12-2008.

CONFLICT OF INTEREST: None.