

## Maxillary necrosis related to treatment with or bisphosphonates

Sir,

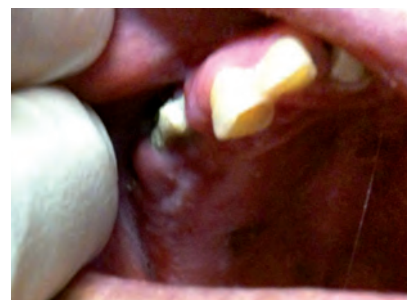In the emergency department (ED), as well as patients with life threatening conditions, we daily attend many patients with unremarkable or nonspecific signs or symptoms; after ruling out an urgent process, a syndromic diagnosis is often made and symptomatic treatment prescribed. When patients do not suffer a trivial or self-limiting process, they consult various areas of health care and finally end up at the ED, sometimes repeatedly. Some of these patients have processes that, although infrequently, induce the emergency physician to prescribe definitive treatment without exhausting the list of diagnostic tests, as happened in the following case.

A 70 year-old woman attended the ED for left hemifacial pain. She had a history of rheumatoid arthritis with positive rheumatoid factor, osteoporosis and lumbar arthrosis and with vertebral collapse and spinal stenosis. She had also been diagnosed with high blood pressure and chronic depressive syndrome. Her medication consisted of: verapamil 180 mg / trandolapril 2 mg 1 tablet per day, esomeprazole 20 mg per day; halazepam 40 mg every 12 hours, leflunomide 20 mg per day, 1,500 mg calcium carbonate / cholecalciferol 400 IU per day, alendronate 70 mg per week and 6 mg deflazacort per day, the latter two taken during 5 years. About a month before the ED visit, the patient began to suffer pain in the area of the upper left premolars, with oral expulsion of purulent, bloody content. Her primary care doctor prescribed treatment with amoxicillin 875 mg/clavulanic acid 125 mg and ibuprofen 600 mg, which did not improve the symptoms. She had no fever but, from about 4 days before, had signs of inflammation in the left hemifacial region, including the periorbital area. Physical examination revealed pain on palpation of the left malar and periorbital jaw, with edema, local temperature increase, and redness. She also showed marked conjunctival inflammation, but slit-lamp examination revealed no corneal or other lesions. Inspection of the oral cavity revealed missing and broken teeth, several with caries, in the upper left quadrant, with a protruding grayish-green lesion in the upper left gingival

area, at the level of the teeth 23-24, compatible with osteonecrosis of the jaw (Figure 1). Laboratory tests showed leukocytes of 16,780/mm<sup>3</sup>, and C-reactive protein 65 mg / L. Facial computed tomography scan showed localized heterogeneous lesions in both upper maxillary arches compatible with osteonecrosis, bilateral exophthalmos more pronounced in the left eye, with increased density subcutaneous fat of the eyelid and left facial tissue. The final diagnosis was left hemifacial cellulitis due to osteonecrosis of the (left) jaw (ONJ), presumably caused by oral bisphosphonates, which acted as an adjuvant in corticosteroid treatment. The patient was admitted for surgery to the department of oral and maxillofacial surgery. She received intravenous antibiotics, and underwent maxillary sequestrectomy and pre-molar extraction, with a favorable outcome.

ONJ is the exposure of bone in the oral cavity and subsequent necrosis, often in connection with dental manipulation or trauma. Clinically it is characterized by mandibular involvement, jaw pain, mucosal ulceration and signs of oral inflammation with infection of the jaw or maxilla, associated with a recent history of dental surgery and chronic exposure to bisphosphonates<sup>1</sup>. The most common symptom is local pain of the affected area; physical examination shows a gingival mucous ulcer with exposure of necrotic bone, sometimes accompanied by purulent secretion. It can progress to the formation of a fistula and pathologic fractures<sup>1</sup>.

Its etiology is not well clarified but has been attributed to a deficit of vascular supply, hypercoagulable states, dental infections and osteomyelitis. The mechanism by which bisphosphonates can cause ONJ is not well defined, but may be caused by intraosseous vascularization secondary to the antiandrogenic properties of these drugs<sup>2,3</sup>. No other location of this bone disease has been reported, so it is believed that contamination of exposed bone by the microflora of the oral cavity (especially during dental procedures) may play an important role in the appearance of ONJ. The risk of developing ONJ in patients on oral low-dose bisphosphonates (for osteopenia, osteoporosis, Paget's dis-



**Figure 1.** Protruding lesion with necrotic base and exposure of bone in the upper left gingival area, at the level of teeth 23-24, compatible with osteonecrosis of the jaw.

ease) is 0.01%-0.04%, which increases to 1-15% with high-dose intravenous treatment of bone metastasis<sup>4,5</sup>.

Bisphosphonate-associated ONJ (B-ONJ) is distinguished from classical osteonecrosis, which is associated with glucocorticoids, radiotherapy or chemotherapy and usually occur on the femoral head<sup>3</sup>. B-ONJ is defined as the presence of exposed bone in the maxillofacial region for more than eight weeks in the absence of radiotherapy, but with the presence of bisphosphonates use<sup>1</sup>. The diagnosis is made clinically, after excluding local malignancy. Numerous cases of ONJ have been reported in patients receiving antitumor treatment with intravenous bisphosphonates<sup>2,3</sup>. Patients with multiple myeloma treated with intravenous bisphosphonates, especially zoledronic acid, and bearing dental prosthesis or undergoing dental surgery, show a higher incidence of ONM<sup>3</sup>. The pathogenesis of this type of ONJ has been associated with a localized bone vascular failure secondary to angiogenesis produced by zoledronic acid. More than 90% of patients with ONJ are cancer patients receiving intravenous bisphosphonates. There are also some published reports of ONJ and bisphosphonate therapy in rheumatoid patients with arthritis<sup>3</sup>, although it is unclear whether this is due to oxidative stress in this disease or to other circumstances inherent in these patients (corticosteroids, immunotherapy, inflammatory mandibular processes etc.). As for non-surgical treatment of

B-ONJ, 20 mg per day of subcutaneous teriparatide (recombinant human parathyroid hormone 1-34) has recently been tested, with good results<sup>6,7</sup>.

In conclusion, emergency physicians should be alert to this possibility in all patients receiving intravenous or prolonged oral bisphosphonates and consulting for a clinical picture compatible with B-ONJ. This picture may be yet another of the many adverse events (up to 12%) associated with bisphosphonates detected in emergency departments<sup>8</sup>.

## References

- 1 Aliya K. Osteonecrosis of the jaw and bisphosphonates. Low doses for osteoporosis seem to be safe. *BMJ*. 2011 (en prensa).
- 2 Calvo-Villas JM, Tapia Torres M, Govantes Rodríguez J, Carreter de Granda E, Sicilia Guillén F. Osteonecrosis del maxilar en pacientes con mieloma múltiple durante y después del tratamiento con ácido zoledrónico. *Med Clin (Barc)*. 2006;127:576-9.
- 3 Santos C, Alegre C. Osteonecrosis maxilar, bifosfonatos y artritis reumatoide. *Med Clin (Barc)*. 2008;130:37-9.
- 4 Yamashita J, McCauley LK, Van Poznak C. Updates on osteonecrosis of the jaw. *Curr Opin Support Palliat Care*. 2010;4:200-6.
- 5 Filleul O, Crompot E, Saussez S. Bisphosphonate-induced osteonecrosis of the jaw: a review of 2,400 patient cases. *J Cancer Res Clin Oncol*. 2010;136:1117-24.
- 6 Cheung A, Seeman E. Teriparatide Therapy for Alendronate-Associated Osteonecrosis of the Jaw. *N Engl J Med*. 2010;363:2473-4.
- 7 Grey A. Teriparatide for bone loss in the jaw. *N Engl J Med*. 2010;363:2458-9.
- 8 Tomás S, Chanovas M, Roqueta F, Alcaraz J, Toranzo T y Grupo de trabajo EVADUR-SEMES EVADUR. Eventos adversos ligados a la asistencia en los servicios de urgencias de hospitales españoles. *Emergencias* 2010;22:415-28.

Francisco de Borja QUERO ESPINOSA,  
Águeda María JIMÉNEZ AGUILAR,  
María Ángeles GARCÍA VÁZQUEZ,  
Francisco Javier MONTERO-PÉREZ

Hospital Universitario Reina Sofía de Córdoba, Spain.

## Chronic lumbar pain in the elderly. Is it always what it seems to be?

Sir,

A 63 year-old woman attended the emergency department for lower back pain of 2 years duration, causing difficulty walking, without numbness or sphincter alteration. Diagnosed with arthritis, she had been evaluated repeatedly in the ED and hospital trauma departments for pain, but without symptom improvement. He reported recent worsening after an accidental fall. Medical history included hyperten-

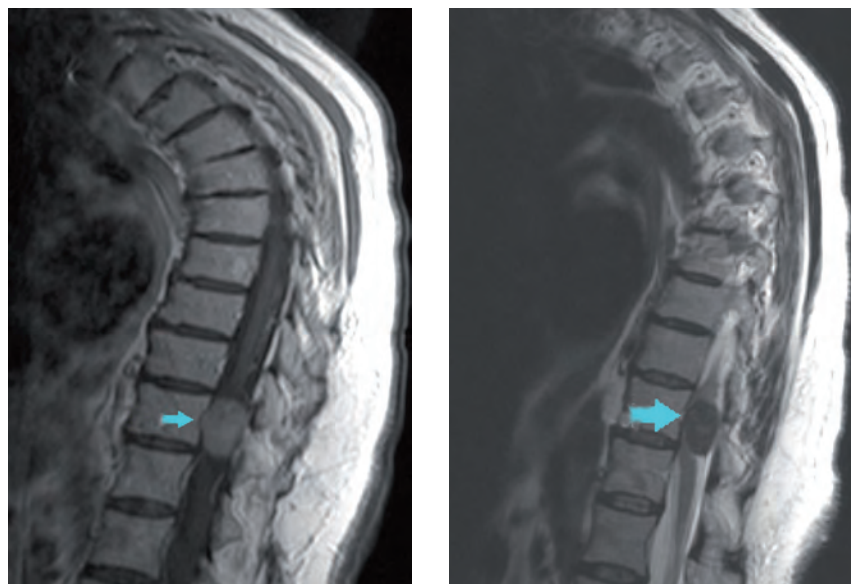sion, chronic heart failure and atrial fibrillation treated with a beta blocker, warfarin, torsemide, and several analgesics. Physical examination revealed lumbar apophysis, 4/5 spastic paresis in the left lower limb and 2/5 in the right lower limb, and hyperreflexia. Laboratory tests showed a prothrombin time of 61% and lumbar x-ray radiography showed scoliosis and L5-S1 osteoarthritis. Magnetic resonance imaging (MRI) of the thoracolumbar spine revealed an intradural, extramedullary, right posterolateral spinal tumor in D11, hypointense with respect to the spinal cord, enhanced after the administration of contrast medium (Figure 1), as well as lumbar osteoarthritis with scoliosis. The tumor was pathologically confirmed as a spinal cord meningioma. It was excised by laminectomy. Postoperative course was uneventful, and the patient made a remarkable recovery, especially of the lower right leg.

The incidence of spinal meningioma is low, 8 per million population per year, predominantly in adults and the elderly<sup>1,2</sup>. The intradural and extramedullary location is typical, accounting for 25% of spinal tumors. They grow slowly so the duration of symptoms from onset to diagnosis can vary from 4 months to 2 years<sup>3</sup>. Clinically they manifest with localized pain in the back and neurological signs secondary to spinal cord compression, such as decreased muscle strength and alterations in sensitivity. MRI is the diagnostic test of choice, providing information on location, extent and relationship with the bone, which is most useful in planning the surgical procedure. Pathologically, meningothelial and psam-

matous tumors are the most frequent (60% and 25% respectively)<sup>1,2</sup>. Prognosis is good, with a mortality rate of less than 3%, and there is rapid recovery of neurological deficits after surgery. Although rare, the development of a cerebrospinal fluid fistula, significant loss of strength and recurrence are the main complications reported<sup>4,5</sup>. In conclusion, not all lower back pain in older people is necessarily due to osteoarthritis, and initially unsuspected serious disease may be present. The history of recent trauma, tumors, infections, prolonged steroid therapy, and the presence of constitutional syndrome, fever<sup>6</sup>, pain at night, loss of limb strength and lower sphincter control, murmurs or abdominal mass<sup>7</sup> are warning signs that should be systematically explored in the ED in the elderly patient with low back pain.

## References

- 1 Gelabert-González M, García-Allut A, Martínez-Rumbo R. Spinal meningiomas. *Neurocirugía*. 2006;17:125-31.
- 2 Pardo J, Lema M. Meningiomas espinales. En: Lema M, Gelabert M. (eds). *Meningiomas*. Santiago de Compostela: Servicio de publicaciones de la Universidad de Santiago de Compostela; 2002. pp. 263-275.
- 3 Ketter R, Henn W, Niedermayer I, Steilen-Gimbel H, König J, Zang KD. Predictive value of progression-associated chromosomal aberrations for the prognosis of meningiomas: a retrospective study of 198 cases. *J Neurosurg*. 2001;95:601-7.
- 4 Sandalcioğlu IE, Hunold A, Müller O, Bassiouni H, Stolke D, Asgari S. Spinal meningiomas: critical review of 131 surgically treated

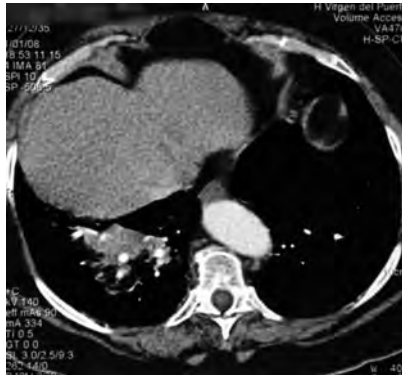


**Figure 1.** Contrast-enhanced dorso-lumbar MRI showing homogeneous tumor 2.5 x 1.5 cm in D11 (arrow) that compresses and displaces the spinal cord, consistent with meningioma.

- patients. *Eur Spine J.* 2008;17:1035-41.
- 5 Gottfried ON, Schmidt MH. Management of spinal meningiomas. *Contemporary Neurosurg.* 2003;25:1-4.
- 6 Franco M, Martínez FJ, Borrachero C, Rodríguez J, Carrasco FJ. Diagnóstico de la espondilodiscitis brucelar en urgencias. *Emergencias.* 2009;21:386-8.
- 7 Pérez MJ, Pérez JL, Varela F, Gómez A, Rosado R. Lumbalgia y osteólisis vertebral como primera manifestación de un aneurisma de aorta abdominal. *Emergencias.* 2001;13:283-6.

Pablo FRANQUELO MORALES,  
Beatriz VALERO SERRANO,  
Juan Ramón TOLEDO GÓMEZ,  
Carlos HERRÁIZ DE CASTRO

*Servicio de Urgencias. Hospital Virgen de la Luz.  
Cuenca, Spain.*



**Figura 1.** Chest CT scan showing segmental atelectasis and adjacent infiltrate in the left lung, indicative of pneumonitis.

## Bronchial foreign body: diagnostic difficulties

Sir,

In emergency medicine there is probably no disease with such a wide variety of presentations as foreign body aspiration<sup>1-4</sup>. In April 2009, the international press reported on an exceptional finding - a pine branch 5 cm long was found in the lung of a patient in western Russia who had consulted for hemoptysis<sup>5</sup>. Although the finding was challenged by the scientific community, there was speculation on the possibility that there had been aspiration of a seed some time before.

A 72 year-old woman with a history of type 2 diabetes mellitus, high blood pressure, obesity and chronic bronchitis consulted the ED on January 1 for cough with hemoptysis of three days duration, without fever or chest pain. Physical examination showed slight hypophonesis in the right lung base. Laboratory tests showed discrete leukocytosis with neutrophilia (11,600 cells/ul and 10,600 neutrophils/ul), respiratory failure (pO<sub>2</sub> 51.1 mmHg, pCO<sub>2</sub> 30.3 mmHg, pH 7.46, HCO<sub>3</sub> 21.4 mmol/l) and D-dimer of 2,117 ng/ml. Chest x-ray showed an elevated right hemidiaphragm without other findings of interest. Chest CT showed a collapsed segment 9 of the left lower lobe with adjacent infiltrate compatible with pneumonitis (Figure 1). With a diagnosis of suspected obstructive atelectasis, the patient was admitted and treated with bronchodilators, intravenous steroids and antibiotics, without improvement, so flexible bronchoscopy was requested. After aspiration of traces of blood in the right bronchial tree, a hard triangular foreign body was extracted; pathological examination indicated it to be of probable plant origin. After re-interrogation, the patient and family members recalled an episode of choking on "almond nougat" the previous week,

coinciding precisely with Christmas festivities when these sweets are traditionally eaten.

In the adult population, bronchial foreign bodies are a rare clinical entity but remain potentially serious, responsible for some 3,000 deaths per year, mostly without prior hospital assessment<sup>6</sup>. Only 6% of cases of foreign body aspiration occurs in people > 14 years; the population groups most at risk include the elderly, the mentally handicapped and individuals with swallowing disorders<sup>7</sup>. The initial aspiration usually manifests as cough, dyspnea, choking, but may sometimes go unnoticed until later episodes of bronchospasm or recurrent pneumonia, and may be confused with other diseases such as bronchitis, bronchiectasis and pneumonia, as in the present case. In our increasingly technical clinical practice based on complementary tests, a good medical history remains essential in patient assessment, although it is sometimes complicated in the ED due to the workload<sup>8</sup> and prioritization of time-dependent processes<sup>9,10</sup>.

## References

- Erol MM, Tekinbas C, Ozsu S, Turedi S, Gunduz A. An unusual tracheobronchial foreign body. *Emerg Med J.* 2008;25:236.
- Jarma Antacle N, Bové Ribé A. Cuerpo extraño impactado en bronquio principal izquierdo. *Emergencias.* 2008;20:363.
- Fernández Baena M, García Pérez AM. Fragmento de antena de metal en árbol tráqueobronquial. *Rev Esp Anestesiología Reanim.* 2009;56:461.
- Guerra del Barrio E, Escribano Sevillano D, Sánchez Gómez FJ, Ojer Tsakiridu D. Condensación pulmonar en el adulto tras consulta con odontólogo. *Rev Clin Esp.* 2004;204:236-7.
- ABC. Encuentran un árbol creciendo en el pulmón de un paciente. (Consultado 15 Septiembre 2010). Disponible en: <http://www.abc.es/blogs/nieves/public/post/encuentran-un-arbol-creciendo-en-el-pulmon-de-un-paciente-892.asp>
- Boyd M, Chatterjee A, Chiles C, Chin R Jr. Tracheobronchial foreign body aspiration in adults. *South Med J.* 2009;102:171-4.
- Digoy GP. Diagnosis and management of upper aerodigestive tract foreign bodies. *Otolaryngol Clin North Am.* 2008;41:485-96.
- Ovens H. Saturación de los servicios de urgencias. Una propuesta desde el Sistema para un problema del Sistema. *Emergencias.* 2010;22:244-6.
- Álvarez Rodríguez V, Merlo Loranca M, Cuesta R., Torices MM, Ruiz Polaina MJ, Martín Martínez A, Guardiola Vicente JS. Análisis del impacto y manejo de la pandemia de gripe A H1N1 en el servicio de urgencias de un hospital terciario. *Emergencias.* 2010;22:181-6.
- Hamilton BH, Hollander J. Diagnóstico del síndrome coronario agudo en los servicios de urgencias: mejoras durante la primera década del siglo XXI. *Emergencias.* 2010;22:293-300.

Montserrat ZARAGOZA FERNÁNDEZ,  
Javier ESCUDERO MUÑOZ,  
Antonia MAYA CASTAÑO,  
María Ángeles SÁNCHEZ QUIROGA

*Servicio de Urgencias. Hospital Virgen del Puerto.  
Plasencia. Cáceres, Spain.*

## Reflections on the current use of angiotensin-converting enzyme inhibitors to treat angioedema

Sir,

Recently, Cordoba Lopez et al<sup>1</sup> published an article in *EMERGENCIAS* involving a case of angioedema due to enalapril with severe obstruction of the airway. The authors provide an excellent clinical description of the case, and review the precise patho-physiology of this life-threatening process. However, we would like to offer some remarks about current treatment.

As the authors state, increased levels of bradykinin play an important role in the pathogenesis of ACEI-induced angioedema, by decreasing the degradation that ACEI cause<sup>1,2</sup>. Moreover, bradykinin contributes to the hypotensive effect of ACEI in the short-term and to inhibition of the renin-angiotensin system precisely through its agonist action on the bradykinin receptor<sup>3</sup>.

There is now a bradykinin antagonist, icatibant<sup>4,5</sup> available in Spain, marketed under the name Firazyr<sup>®</sup>. It is a selective and specific antagonist of the bradykinin receptor B (2), approved for use in hereditary angioedema<sup>7-10</sup> and also effective in ACEI-induced angioedema<sup>11,12</sup>. Icati-



bant is used with doses of 30 mg (one pre-loaded syringe) administered subcutaneously, preferably in the abdominal region. This dose may be repeated every 6 h, in case of recurrence or persistence of symptoms, but may not exceed 90 mg in 24 hours<sup>13</sup>.

Other drugs are also used in hereditary angioedema, such as ecallantide<sup>10,14</sup> (a specific and powerful plasma kallikrein inhibitor, not marketed in Spain), without any reported results on effectiveness in the treatment of ACEI-induced angioedema. Then there is the well-known C<sup>1</sup> inhibitor (Berinert®)<sup>6</sup>, which is low in hereditary angioedema (but not in ACEI-induced angioedema)<sup>9</sup>, with reported effectiveness in treating this important adverse effect of ACEIs<sup>15</sup>.

The use of specific drugs for angioedema with severe obstruction of the airway, whether hereditary or ACEI-induced, has been shown to avoid the need for endotracheal intubation or other invasive methods to open the airway. They are therefore preferred over the standard treatment used in allergic processes (glucocorticoids, antihistamines), with poor effectiveness in angioedema which, we would emphasize, is a non-allergic process<sup>11,15-19</sup>.

## References

- 1 Córdoba López A, Granado Martínez D, Pérez Frutos MD, Jimeno Torres B. Insuficiencia respiratoria grave secundaria a angioedema por enalapril. *Emergencias*. 2010;23:80.
- 2 Taki M, Watanabe H, Hasegawa T, Bamba H, Shimada T, Hisa Y. Angioedema: 6 years experience with fourteen cases. *Auris Nasus Larynx*. 2010;37:199-204.
- 3 Gainer JV, Morrow JD, Loveland A, King DJ, Brown NJ. Effect of bradykinin blockade on the response to angiotensin-converting-enzyme inhibitor in normotensive and hypertensive subjects. *N Engl J Med*. 1998;339:1285-92.
- 4 Cruden MLM, Newby DE. Therapeutic potential of icatibant (HOE-140, JE-049). *Expert Opin Pharmacother* 2008; 9: 2383-90.
- 5 Deeks ED. Icatibant. *Drugs*. 2010;70:73-81.
- 6 Ministerio de Sanidad, Igualdad y Política Social. Centro de Información online de Medicamentos de la Agencia Española de Medicamentos y Productos Sanitarios. (Consultado Abril 2011). Disponible en: <https://sinaem4.agemed.es/consaem/fichasTecnicas.do?metodo=buscar>
- 7 Cicardi M, Banerji A, Bracho F, Malbrán A, Rosenkranz B, Riedl M, et al. Icatibant, a new bradykinin-receptor antagonist, in hereditary angioedema. *N Engl J Med*. 2010;363:532-4.
- 8 Cicardi M, Levy RJ, McNeil DL, Li HH, Sheffer AL, Campion M, et al. Ecallantide for the treatment of acute attacks in hereditary angioedema. *N Engl J Med*. 2010;363:523-31.
- 9 Zuraw BL. Hereditary angioedema. *N Engl J Med*. 2008;359:1027-36.
- 10 Nagy N, Grattan CE, McGrath J. New insights into hereditary angio-oedema: Molecular diagnosis and therapy. *Australas J Dermatol*. 2010;51:157-62.
- 11 Bas M, Greve J, Stelter K, Bier H, Stark T, Hoffmann TK, et al. Therapeutic efficacy in angioedema induced by angiotensin-converting enzyme inhibitors: a case series. *Ann Emerg Med*. 2010;56:278-82.
- 12 Schmidt, Peter W. Hirschl M, Trautinger F. Treatment of angiotensin-converting enzyme inhibitor-related angioedema with the bradykinin B2 receptor antagonist icatibant. *J Am Acad Dermatol*. 2010;63:913-4.
- 13 Montero Pérez FJ, García Núñez I, Guerra Pasadas F, Jiménez Murillo L. Urticaria, angioedema y anafilaxia. En: Jiménez Murillo L, Montero Pérez FJ. *Medicina de Urgencias*. Guía terapéutica. Madrid: Elsevier Spain S.L., 2011.
- 14 Morgan BP. Hereditary Angioedema — Therapies Old and New (Edit.). *N Engl J Med*. 2010;363:581-3.
- 15 Nielsen EW, Gramstad S. Angioedema from angiotensin-converting enzyme (ACE) inhibitor treated with complement 1 (1) inhibitor concentrate. *Acta Anaesthesiol Scand*. 2006;50:120-2.
- 16 Avilés FJ, Planas K, Tobed M, Doménech E, Pobo A, Figuerola E. Angioedema por inhibidores de la enzima convertidora de angiotensina. *Med Clin (Barc)*; 2010;134:664.
- 17 Hussain N, Ahmed N, Ramjug S. A case of airway compromise. *BMJ*. 2010;341:c3822.
- 18 Kupfer Y, Ramachandran K, Tessler S. ACE inhibitor-induced angioedema in elderly African American females requiring tracheostomy. *J Natl Med Assoc*. 2010;102:529-30.
- 19 De Knop KJ, Hagendorens MM, Stevens WJ, De Clerck LS, Ebo DG. Angioedema beyond

histamine: an educational case series. *Acta Clin Belg*. 2010;64:520-8.

Francisco Javier MONTERO-PÉREZ,  
José Manuel CALDERÓN DE LA BARCA  
GÁZQUEZ, Luis JIMÉNEZ MURILLO

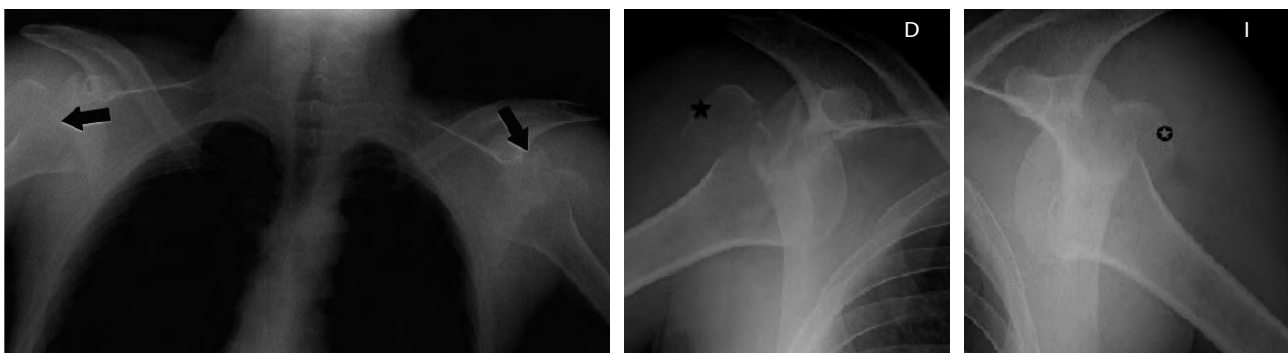*Unidad de gestión clínica de Urgencias.  
Hospital Universitario Reina Sofía.  
Córdoba, Spain.*

## Bilateral shoulder fracture and dislocation of the secondary to convulsions

Sir,

A 27 year-old man with no relevant medical history except alcoholism under treatment visited the emergency department (ED) after a short witnessed episode of tonic-clonic seizure with post-critical state. Physical examination showed normal cardiopulmonary auscultation, without focal neurological signs, but swelling and loss of function of both shoulders and both arms in abduction and internal rotation. Plain x-ray of both shoulders showed posterior dislocation and bilateral trochanteric fracture (Figure 1). We performed a closed reduction of both shoulders and immobilization with a bilateral sling bandage and the patient was referred for definitive surgical treatment of the trochanteric fracture.

The incidence of bilateral shoulder fracture-dislocation is low (2%) and mainly affects young men<sup>1</sup>. Although such shoulder injuries can be caused by high-energy impact, they are typically the consequence of tonic-clonic seizure, electric shock therapy and accidental electric shock<sup>2</sup>. Clinically, external rotation block is a characteristic finding<sup>3</sup>. The posterior shoulder is prominent and the anterior surface is flattened, leading to an "empty" compartment of the shoulder on palpation<sup>4</sup>. More than 50% of these disloca-



**Figure 1.** Posteroanterior chest x-ray (left) showing bilateral posterior shoulder dislocation (arrows) associated with bilateral humeral trochanteric fracture (center image star, and right image circle).

tions are undetected in the initial x-ray<sup>5</sup>, so they remain undiagnosed and may lead to adhesive capsulitis ("frozen shoulder"). Radiologically, in the anteroposterior x-ray, it is impossible to identify the glenohumeral interline. In cases of diagnostic doubt with x-ray imaging, computed tomography (CT) scan is recommended. In conclusion, seizure is the single most frequent cause of posterior shoulder dislocation. The lesion is difficult to diagnose because clinical signs are not too clear and plain x-rays are difficult to interpret, so it must be suspected and recognized clinically and radiologically.

## References

- 1 Miralles Marrero R. Valoración del daño corporal en el aparato locomotor. Parte II. Barcelona: Masson; 2001. pp. 85.
- 2 Swiontkowski MF. Manual de ortopedia y traumatología 2 ed. Cap 16 lesiones agudas del hombro. Barcelona: Masson; 2004. pp. 211.
- 3 Jenkins JL, Braen RG. Manual de Medicina de urgencias 3. Barcelona: Elsevier; 2003. pp. 86.
- 4 Taylor RB. Medicina de familia principios y práctica. Barcelona: Masson; 2006. pp. 1027.
- 5 Ferri FF. Consultor clínico 2006-2007 Claves diagnósticas y tratamiento. Barcelona: Elsevier; 2006. pp. 528.

Daniel GARCÍA MARTÍN,  
María Ángeles SALBALICH,  
Carmen PEINADO ROSADO,  
Rubén Óscar DIMARCO  
*Servicio de Urgencias.  
Hospital de Manacor. Mallorca, Spain.*

## Cardiac death donors

Sir,

We have read with interest the article entitled "Emergency staff attitudes toward organ donation after cardiac death"<sup>1</sup>. As mentioned in the article and demonstrated by the extensive literature on the subject, a lack of organs makes it increasingly necessary to initiate new programs at the national level and greater use of organs procured in those programs currently in operation<sup>2</sup>. We are pleased that out-of-hospital emergency professionals share our view on the usefulness of these programs to increase the number of donors. We agree with the authors that communication with family members and proposing organ donation is always difficult. However, as is evident in different publications, the percentages of family acceptance and generosity

about organ donation are low<sup>2,3</sup>. Of course, the training of professionals in this task is a cornerstone of organ donation programs, both in cases of brain death and heart arrest. It is gratifying to see the level of acceptance of non-heart beating donor programs by emergency physicians, who are fundamental for their implementation<sup>4,6</sup>.

We would like to point out that, regardless of when the protocol is activated, this is a dynamic process which must ensure rigorous application of donor inclusion and exclusion criteria<sup>6</sup>. The joint effort and collaboration between emergency services and hospital services (transplant coordination, internal medicine, intensive care, emergency services) makes these programs a source of high quality organs, which have produced results similar to those of brain-death transplants<sup>6-10</sup>.

## References

- 1 Mateos Rodríguez A, Sánchez Brunete Ingelmo V, Navalpotro Pascual JM, Barba Alonso C, Martín Maldonado ME. Actitud de los profesionales de emergencia ante la donación de órganos tras una muerte cardiaca. *Emergencias*. 2011;23:204-7.
- 2 Organización Nacional de Trasplantes [sede web]. Madrid: ONT; 2010. (Consultado 4 Abril 2011). Memoria Donantes 2010. Disponible en: [http://www.ont.es/infesp/Memorias/Memoria\\_Donantes\\_2010.pdf](http://www.ont.es/infesp/Memorias/Memoria_Donantes_2010.pdf)
- 3 Scandroglio B, Domínguez-Gil B, López JS, Valentín MO, Martín MJ, Coll E, et al. Analysis of the attitudes and motivations of the Spanish population towards organ donation after death. *Transpl Int*. 2011;24:158-66.
- 4 Deulofeu R, Blanca MA, Twose J, Matesanz R; en representación de los investigadores del grupo de trabajo del plan estratégico de negativas familiares de la Organización Nacional de Trasplantes. Actitud y conocimiento sobre la donación y el trasplante de órganos y tejidos de médicos de atención primaria, emergencias y urgencias en Spain. *Med Clin (Barc)*. 2011;136:541-8.
- 5 Matesanz R. Papel de los Servicios de Urgencias y Emergencias en la donación de órganos. *Emergencias*. 2010;22:68-71.
- 6 Del Río-Gallegos F, Escalante-Cobo JL, Nuñez-Pena JR, Calvo-Manuel E. Donación tras la muerte cardiaca. Parada cardiaca en el donante en muerte encefálica. *Med Intensiva*. 2009;33:327-35.
- 7 Del Río F, Núñez JR, Soria A, Moreno MA, Varela A, Calatayud J. Non Heart beating donors. Successfully expanding the donor's pool. *Ann Transplant*. 2004;9:19-20.
- 8 Rodríguez DA, Del Río F, Fuentes ME, Naranjo S, Moradiellos J, Gómez D, et al. Trasplante de pulmón con donantes no controlados a corazón parado. Factores pronósticos dependientes del donante y evolución inmediata postrasplante. *Arch Bronconeumol*. 2011;47:403-9.
- 9 Gallegos FdR. Incrementar el número de pulmones válidos para trasplante: una necesidad. *Med Intensiva*. 2011. doi:10.1016/j.medint.2011.05.009

- 10 Sánchez-Fructuoso AI, Marqués M, Prats D, Conesa J, Calvo N, Perez-Contín MJ, et al. Victims of cardiac arrest occurring outside the hospital: a source of transplantable kidneys. *Ann Intern Med*. 2006;145:157-64.

Diego RODRÍGUEZ SERRANO<sup>1</sup>,  
Francisco DEL RÍO GALLEGOS<sup>1</sup>,  
Federico GORDO VIDAL<sup>2</sup>,  
Miguel SÁNCHEZ<sup>1</sup>

<sup>1</sup>Servicio de Medicina Intensiva. Hospital Clínico San Carlos. Madrid, Spain.

<sup>2</sup>Servicio de Medicina Intensiva. Hospital del Henares. Coslada. Madrid, Spain.

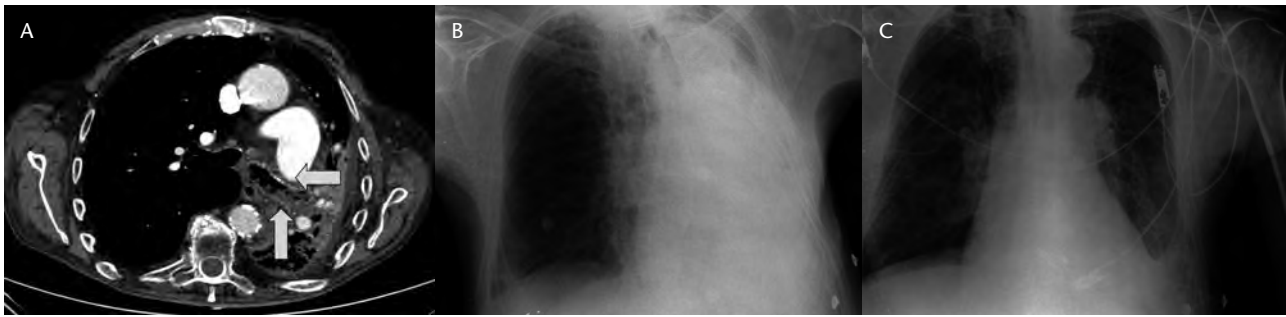
## Left lung collapse: resolution after bilevel positive airway pressure ventilation

Sir,

Increased mucus production in chronic obstructive pulmonary disease (COPD) is well known. In advanced stages of the disease, deterioration of respiratory function and other auxiliary factors (chest wall musculature, cough, etc.) hinder the clearance of secretions, as occurs in some patients with neuromuscular disease. The formation of mucous plugs may cause collapse of the lung lobes or the entire lung, and lobar atelectasis becomes a cause of COPD exacerbation.

This case was an 83 year-old man with long-standing COPD, chronic renal failure and secondary anemia, who had undergone aortobifemoral bypass surgery in 2002. In the last month he had been hospitalized three times for pneumonia of the left lower lobe. On this occasion it was decided to use computed tomography (CT) scan of the chest to rule out endobronchial malignancy. The scan showed hypodense content in the left main bronchus suggestive of a mucus plug (Figure 1A). At 48 hours the patient showed increased work of breathing, severe respiratory failure (pH 7.38 / pCO<sub>2</sub> 56 mmHg/pO<sub>2</sub> 31 mmHg) with progressive deterioration of consciousness. Urgent x-ray showed massive atelectasis of the left lung (Figure 1B). Treatment in the intermediate care unit of the ED with non-invasive ventilation (BIPAP) was given in order to relieve the dyspnea. After 8 hours of ventilation, the patient showed improved blood gases and clinical parameters, and resolution of the atelectasis (Figure 1C).

Atelectasis due to mucous plugs causes exacerbation in COPD, with a severity directly related to the extent of alveoli collapse. Fiberoptic bronchoscopy is an invasive method which has proved effective in resolving these events<sup>1</sup>, and it is a common procedure in patients with prolonged intubation in critical care or postoperative care units<sup>2</sup>. In recent years, different modes



**Figura 1.** (A) Chest CT scan showing atelectasis and bronchial mucus plug (arrows). (B) Chest x-ray showing massive left lung atelectasis. (C) Chest x-ray showing resolution after treatment with BiPAP.

of noninvasive mechanical ventilation have been used to resolve the frequent complications of COPD and other diseases with neuromuscular respiratory failure, and in some cases endotracheal intubation has been avoided. The application of positive pressure in the airway is beginning to be reported as an effective mechanism to help mucociliary clearance in COPD, with even better results than those obtained with older techniques commonly used before<sup>3</sup>. There are few published reports of atelectasis resolution using BiPAP or CPAP, such as the present case. Some devices, such as cough-assist, apply to patients with cystic fibrosis or neuromuscular disease, to prevent the formation of mucus plugs or to eliminate them when they do occur<sup>4</sup>. In many cases, they already form part of home treatment of this type of patient.

## References

- 1 Gea G, Hitado J. Indicaciones de la fibrobroncoscopia. *Medicine*. 2002;8:4110-1.
- 2 Ferreira GP, Baussano I, Squadrone V, Richiardi L, Marchiaro G, del Sorbo L, et al. Continuous positive airway pressure for treatment of respiratory complications after abdominal surgery: a systematic review and meta-analysis. *Ann Surg*. 2008;247:617-26.
- 3 Gilbert C, Marik PE, Varon J. Acute lobar atelectasis during mechanical ventilation: to beat, suck or blow? *Crit Care Shock*. 2009;12:10-3.
- 4 McCool FD, Rosen MJ. Nonpharmacologic airway clearance therapies. *Chest*. 2006;129:250s-259s.

José Antonio NUEVO GONZÁLEZ,  
Juan Carlos CANO BALLESTEROS,  
Juan Antonio ANDUEZA LILLO

*Servicio de Urgencias. Hospital General Universitario Gregorio Marañón. Madrid, Spain.*

## Quality indicators in emergency medicine

Sir,

We have read with interest the article by Mellado et al<sup>1</sup> and would

like to make a contribution to this topic. Work in the emergency department (ED) is subject to increasing pressure and sometimes even chaos. In this context, there are two pillars on which daily practice should be based: adequate personal attention, and sufficiently detailed information, in order to reassure both patients and their family members about their safety at all times in the care process.

Quality indicators can help ED professionals convey this, to the benefit of the patient, and they can facilitate the work performed. However, until recently, there were no specific indicators for the area of ED work. It has taken ED awareness of our role in healthcare for us to start applying tools for improvement previously only used in the field of hospitalization. Therefore, initiatives such as those of the Generalitat de Catalunya<sup>2</sup> and SEMES<sup>3</sup> to develop specific indicators of quality applicable to the ED are a step forward in our view.

Much emergency assistance takes place in district hospitals or even in primary care, and some of these patients require further attention by a referral center, to perform particular diagnostic tests or specialized treatment<sup>4</sup>. Referral to a high-level hospital requires specific indicators, which have not been previously defined<sup>2,3</sup>, such as diagnostic concordance<sup>1</sup>. In addition, inappropriate hospital referral increases health spending. To avoid this, issues such as diagnostic concordance and correct indication for transfer<sup>5</sup> must be addressed, with results such as the need for hospital admission, surgical or orthopedic treatment, imaging tests, specialist assessment, or patient stays longer than 12 hours in the ED or observation units.

Therefore, we would propose

that referral appropriateness<sup>5</sup> be included as a new indicator of quality, together with diagnostic concordance, for all transfers of patients from primary care or district hospitals to higher level emergency departments.

## References

- 1 Mellado Vergel JM, Díaz Ricomá N, Mena Parra D, Rosell Ortiz F, Contreras Rodríguez AM, Jeón Ruiz L. Concordancia diagnóstica entre el servicio de urgencias de un hospital de alta resolución y su hospital de referencia. *Emergencias*. 2010;22:282-5.
- 2 Felisart J, Requena J, Roqueta F, Tomás S, Saura RM, Suñol R. Servicios de urgencias: indicadores para medir los criterios de calidad de la atención sanitaria. <http://www.gencat.cat/salut/depsan/units/aatrm/pdf/br0101es.pdf>.
- 3 Sociedad Española de Urgencias y Emergencias (SEMES). Manual de indicadores de calidad para los Servicios de Urgencias de Hospitales. Ed. SEMRS. Madrid: Grupo Saned; 2009.
- 4 Pérez Martín A, López Lanza JR, Dierssen Sotos T, Villa Puente M, Raba Oruña S, Del Río Madrazo JA. Análisis de las derivaciones hospitalarias desde un servicio de urgencias de Atención Primaria durante un año. *Semerger*. 2007;33:341-8.
- 5 Aranda Cárdenas MD, Álvarez Albarrán MT, Puiggali Ballart M, Puente Palacios I, Laso de la Vega i Artal S, Clemente Rodríguez C. Concordancia de diagnósticos e idoneidad en traslados como índice de calidad asistencial. Libro de Ponencias y Comunicaciones del 26º Congreso de la Sociedad Española de Calidad Asistencial, Zaragoza, 21 a 24 de octubre de 2008. Ed. Sociedad Española de Calidad Asistencial. ISBN 978-84-691-6409-9. Pag. 345.

Carlos CELEMENTE RODRÍGUEZ,  
Dolors ARANDA CÁRDENAS,  
Margarita PUIGGALÍ BALLART,  
Isabel PUENTE PALACIOS<sup>1</sup>

*Servicio de Urgencias. Hospital de l'Esperança. Parc de Salut Mar. Barcelona, Spain.*

## Emergency ultrasound

Sir,

We have read with interest the article by Campos Linares et al. and are



pleased to see the foundation being laid for the use of ultrasound in the emergency department (ED). However, it is a difficult path because of multiple barriers that appear on the way. Obstacles are and have been set up by health managers (budgetary deficits), colleagues in other specialties (little confidence in the work of emergency physicians), and radiologists (alleging intromission) and ourselves (fear of new responsibilities).

Ultrasound techniques that allow us to perform basic studies in the ED are economic and rapidly pay for themselves. The confidence of specialists will be won over time and with results. Studies of concordance in ultrasound findings between emergency physicians and radiologists show highly satisfactory results ( $\kappa$  index: 0.88 to 0.90)<sup>1-3</sup>. Radiologists will come to accept this situation as they have in the case of ultrasound use by other specialties. Perhaps the most difficult obstacle to overcome is the one at home – we ourselves.

Therefore it is essential to initiate training activities with practical courses on the use of ultrasound, and that these then continue with periods of learning in radiology departments, to be prepared and for the ultrasound scanner to become another tool in ED work<sup>4</sup>.

We must not fear what is new and unknown, as we always have done. Ultrasound in the ED is good for all: for the patient, as it decreases overall attention time (especially in regional hospitals with a locatable radiologist) at the same time improving their confidence in the attending physician. It is also good for the radiologist, since on many occasions this scan will provide sufficient guidance, becoming a decision-making tool for emergency physicians to refer particular cases for specialist consultation<sup>5,6</sup>. We must clarify that those patients with an indication for classical ultrasound study should be evaluated by a specialist in radiology.

Finally, emergency physicians will also benefit from this new tool: it is rapid, relatively inexpensive and non-invasive. It allows us to resolve emergent situations, such as in abdominal trauma, and indicates the appropriateness of urgent surgery, thus shortening action times<sup>7,9</sup>. There are many advantages of using this technique in the ED, such as allowing us to rule out hemoperitoneum, hemithorax and hemopericardium in 3-5 minutes,

all performed in the ED bay where the patient is being attended.

As we acquire more skill in ultrasound use, its indications can be established, as suggested Nogué<sup>10</sup>. So we would encourage you to take a step forward without fear: let us use ultrasound in our EDs, our patients will surely appreciate it.

## References

- 1 Campo Linares R, Sanz Cortés J, Morales Cano JM, Gómez San Román T. Valor de la ecografía de extremidades inferiores para el diagnóstico de la trombosis venosa profunda en un servicio de urgencias. *Emergencias*. 2009;21:177-82.
- 2 Blaivas M, Lambert M, Harwood R, Wood JP, Konicki J. Lower-extremity Doppler for deep venous Thrombosis. Can emergency physicians be accurate and fast? *Acad Emerg Med*. 2000;7:120-6.
- 3 Jolly TB, Massarin E, Pigman C. Color Doppler ultrasonography by emergency physicians for the diagnosis of acute deep venous thrombosis. *Acad Emerg Med*. 1997;4:129-32.
- 4 Gracias VH, Frankel HL, Gupta R, et al. Defining the learning curve for the Focused Abdominal Sonogram for Trauma (FAST) examination: implications for credentialing. *Am Surg*. 2001;67:364-8.
- 5 Martín LA, Campo R, Rayo Gutiérrez M. Pericarditis purulenta: diagnóstico ecográfico precoz en el Servicio de urgencias. *Emergencias*. 2008;20:135-8.
- 6 Pintado R, Moya de la Calle M, Sánchez S, Castro MA, Plaza S, Mendo M. Indicación y utilidad de la ecografía en la sospecha de apendicitis aguda en la urgencia. *Emergencias*. 2008;20:81-6.
- 7 Han DC, Rozycki GS, Schmidt JA, Feliciano DV. Ultrasound Turing ATLS: and early satr for surgical interns. *J Trauma*. 1996;41:208-13.
- 8 Rozycki G. Surgeon-performed ultrasound. Its use in Clinical Practice. *Ann Surg*. 1998;228:16-28.
- 9 Catan F, Altamirano C, Salas C, Novoa R, Castro JP, Lagos C, Larrea V. Ecografía realizada por cirujanos en el manejo de pacientes con trauma. *Rev Med Chile*. 2002;892-6.
- 10 Nogué R. La ecografía en medicina de urgencias, una herramienta al alcance de los *urgenciólogos*. *Emergencias*. 2008;20:75-7.

José Manuel RECIO RAMÍREZ,  
Manuel AGUILERA PEÑA,  
Enrique FERNÁNDEZ ROMERO  
*Hospital de Montilla. Córdoba, Spain.*

## Better management of hospital beds by means of warning systems

Sir,

In 2007, the Health Consortium Terrassa (CST) designed a hospital discharge plan based on information and communication technology (ICT), which resulted in a 30% in-

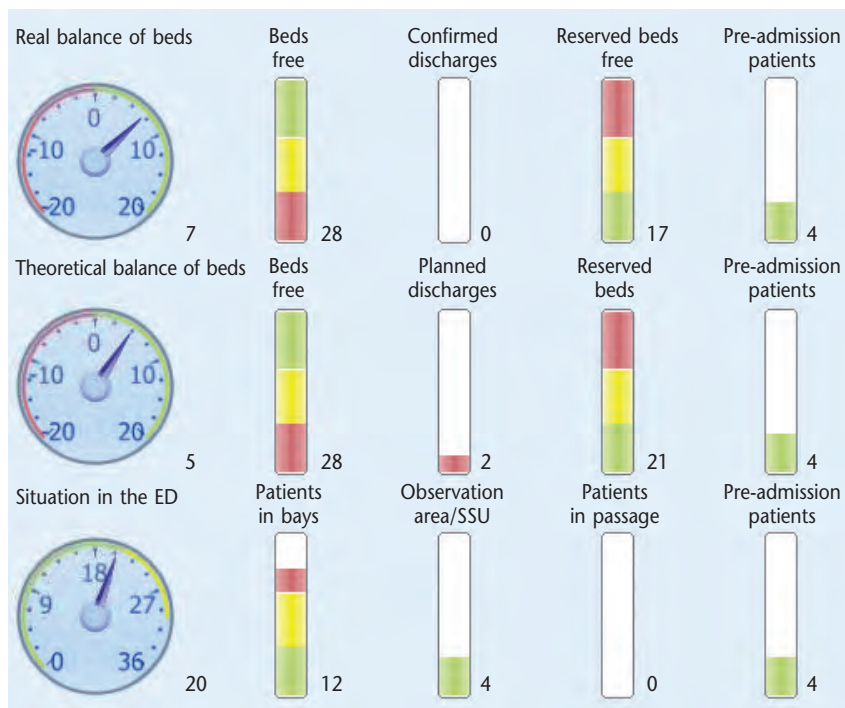
crease of discharges made before 1 pm<sup>1,2</sup>. This improved process provided reliable information on confirmed real-time discharge and that expected 24 hours in advance, and the correlation between the two exceeded 91%. However, these results were often altered during crisis situations due to lack of beds, producing an imbalance between demand and supply. The immediate consequences were delayed admissions, transfers to other centers due to the lack of beds, surgical deprogramming and arbitrary assignment of hospital beds on becoming available<sup>3-5</sup>.

In order to automate and plan a coordinated multidisciplinary response, the computer system was equipped with an alert system, to monitor the predicted capacity to absorb demand for emergency and programmed admissions. We established two monitoring indicators: the balance of real and theoretical beds, for which we introduced the following values: confirmed discharges, planned discharges, reservations, transfers and pending admissions from the emergency department.

Three levels of alert were established (white, green, yellow) according to the balance and ED occupation in real time. The information was displayed through a clinical work station "traffic light" indicating the level of alert (Figure 1). Activation of the alert generated an automatic email to all those involved in the process: crisis committee members, administrative units, department heads, nursing coordinators, management control, ambulance service and catering coordinators.

During the two year follow-up period (2009-2010), the results have demonstrated the effectiveness of CST alerts to solve crises by eliminating transfers to other centers and surgical deprogramming. Likewise, it significantly reduced the time of deactivating the alert and delay in admissions from the ED<sup>6,7</sup>, and thus avoided protracted overcrowding in the ED (Table 1).

In conclusion, the implementation of ICT in a clinical work station has been instrumental in improving the process improvement, and we have not found any reference to similar systems in the literature dealing with planning and management of hospital beds<sup>8</sup>.



**Figure 1.** Clinical work station screen shot at 12am. Dials show a positive real balance, without ED overcrowding. The theoretical balance shows planned discharges up to 3 pm. SSU: short stay unit in the ED.

## References

- García Alonso D, Enjuig N, Valverde L, Castells M, Pascual I, Esquerda A, et al. Resultado de un proceso para la mejora de las altas hospitalarias precoces. *Emergencias*. 2011;23:29-34.
- Achieving timely 'simple' discharge from hospital-A toolkit for the multi-disciplinary team. Department of Health UK 2004. (Consultado 15 Noviembre 2011). Disponible en <http://www.dh.gov.uk>
- Huang Q, Thind A, Dreyer JF, Zaric GS. The impact of delays to admission from the emergency department on inpatient outcomes. *BMC Emerg Med*. 2010;9:10-6.
- Juan A, Enjamio E, Moya C, García Fortea C, Castellanos J, Pérez Mas J. Impacto de la implementación de medidas de gestión hospitalaria para aumentar la eficiencia en la gestión de camas y disminuir la saturación del servicio de urgencias. *Emergencias*. 2010;22:249-53.
- Crilly J. The impact of a temporary medical ward closure on emergency department and hospital service. *Qual Manag Health Care*. 2011;20:322-33.
- Ou L, Chen J, Young L, Santiano N, Baramy LS, Hillman K. Effective discharge planning - timely assignment of an estimated date of discharge. *Aust Health Rev*. 2011;35:357-63.
- Resar R, Nolan K, Kaczynski D, Jensen K. Using real-time demand capacity management to improve hospital wide patient flow. *JtComm J Qual Patient Saf*. 2011;37:217-27.
- Mackay M. Practical experience with bed occupancy management and planning systems: an Australian view. *Health Care Manag Sci*. 2001;4:47-56.

Dolores GARCÍA ALONSO,  
Antonio SÁNCHEZ HIDALGO,  
Xavier TURU,  
Nuria ENGUIX

Consorcio Sanitari de Terrassa. Barcelona, Spain.

**Table 1.** Results

	2008	2009	2010	p
Nº alerts	NA	26	18	
MT-DA (SD) (mins)		707 (1,096)	338 (560)	0.005
Nº surgical de-programming	10	0	0	
Nº transfers to other centers	120	0	0	
UADT (SD) (mins)	NA	638 (400)	364 (115)	0.0001
% Correlation PD/CD				
Medical	98.2	98.3	98.4	
Surgical	91.2	91.5	91.6	

MT-DA: Mean time to de-activation of the alert; SD: standard deviation; PD: planned discharges; CD: confirmed discharges; NA: not applicable (pre-implementation). UADT: urgent admission delay time.

## Kounis syndrome: acute coronary syndrome triggered by allergic reaction

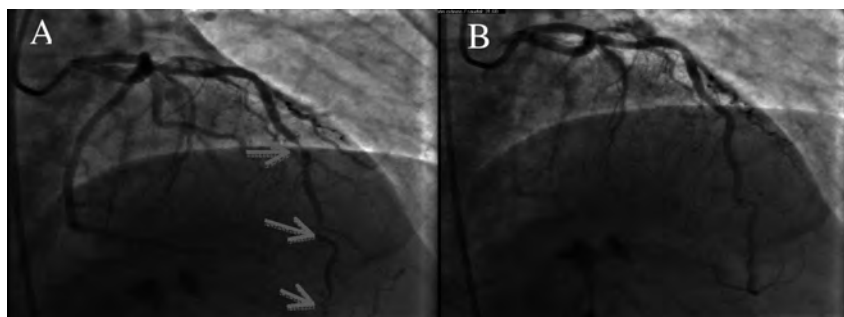
Sir,

Allergic reactions can lead to different cardiovascular events. Kounis and Zavras first described the association between allergic reaction and coronary artery spasm, known as allergic angina syndrome or Kounis syndrome<sup>1-3</sup>. It is defined as a coronary syndrome caused by the release of inflammatory mediators. It has two variants: type I, in patients with normal coronary arteries, where hypersensitivity reactions produce coronary artery spasm, and type II, patients with atheromatous disease, where the spasm produces plaque rupture and coronary thrombosis<sup>2-5</sup>.

A 48 year-old man attended the emergency department (ED) for nocturnal precordial oppression. He had a history of asthma, nasal polyps and intolerance to anti-inflammatory agents. On arrival was asymptomatic, and ECG showed negative waves. He received 300 mg of acetylsalicylic acid (ASA) and 300 mg of oral clopidogrel. In the ED observation area (one hour later), he presented epigastric pain, syncope, stupor and hypotension, but no dyspnea, hives or swelling of the uvula. ECG showed sinus rhythm with anterior, lateral and inferior subepicardial lesion. Following intravenous fluids and steroids, his condition stabilized without the need for adrenaline, with ECG improvement. Coronary angiography showed a severe spasm in the anterior descending arteries (Figure 1), right coronary and posterior lateral arteries, which resolved with intracoronary nitroglycerin, without atherothrombotic lesions. He was subsequently studied by the hospital allergology unit which reported an allergic reaction to ASA as the most likely cause according to the Karch-Lasagna algorithm (no further ASA was administered due to the severity of the previous reaction). He was discharged from hospital with a diagnosis of vasospastic angina secondary to probable allergic reaction to ASA (Kounis syndrome) and treated with calcium antagonist and clopidogrel.

In allergic reactions there is a chain of product release, ranging from histamine, prostaglandins and leukotrienes to platelet aggregation factors, which cause smooth muscle contraction. There are several cases of vasospastic angina complicated by infarction or sudden death syndrome, where an increase of mast cells in place 2-4 of coronary spasm. The allergic reaction may be triggered by drugs<sup>5-8</sup>, contrasts, food<sup>9</sup> or insect bites. The administration of





**Figure 2.** Coronary angiography. A) vasospasm in different segments of the anterior descending artery (arrows). B) Resolution after intracoronary nitroglycerin.

adrenaline is debatable, in relation with the induction of coronary artery spasm, and makes it difficult to distinguish the real cause (anaphylaxis versus adrenaline)<sup>10</sup>. The pathophysiological mechanism underlying Kounis syndrome remains unclear, but the number of reported cases is increasing, and we should include this entity in the differential diagnosis of ischemic heart disease.

## References

- 1 Kounis NG, Zavras GM. Histamine-induced coronary artery spasm: the concept of allergic angina. *Br J Clin Pract.* 1991;45:121-8.
- 2 Kounis NG. Kounis syndrome (allergic angina and allergic myocardial infarction): A natural paradigm? *Int J Cardiol.* 2006;110:7-14.
- 3 Gázquez V, Dalmau G, Gaig P, Gómez C, Navarro S, Mercé J. Kounis Syndrome: Report of 5 Cases. *J Investig Allergol Clin Immunol.* 2010;20:162-5.
- 4 Schwartz BG, Dalmau S, Kuiper J. The Kounis-Zavras syndrome with the Samter-Bertrian triad. *Proc (Bayl Univ Med Cent).* 2011;24:107-9.
- 5 Fox DJ, Gray TP, Fath-Ordoubadi F. Myocardial infarction after aspirin treatment. *J R Soc Med.* 2005;98:21-3.
- 6 Kounis NG, Kounis SN, Koutsojannis CM. Myocardial infarction after aspirin treatment, and Kounis syndrome. *J R Soc Med.* 2005;98:296.
- 7 Kumar A, Berko NS, Gothwal R, Tamarin F, Kounis SS. Syndrome secondary to ibuprofen use. *Intern J Cardiol.* 2009;137:79-80.
- 8 De Groot JWB, Gosselink ATM, Ottervanger JP. Acute ST-Segment Elevation Myocardial Infarction Associated with Diclofenac-Induced Anaphylaxis: Case Report. *AM J Crit Care.* 2009;18:388-386.
- 9 Wada T, Abe M, Yagi N. Coronary vasospasm secondary to allergic reaction following food ingestion: a case of type I variant Kounis syndrome. *Heart Vessels.* 2010;25:263-6.
- 10 Rubio JA, Oteo JF, Maicas C, Cantón T, Barciela R, García JA. Vasoespasmo inducido por adrenalina como forma de presentación de una angina variante. *Rev Esp Cardiol.* 1999;52:273-6.

Sandra RODRÍGUEZ JUSTO<sup>1</sup>,  
Eva GONZÁLEZ BABARRO<sup>2</sup>,  
Eva GARCÍA VILLAR<sup>1</sup>,  
Jesús SANTAMARÍA VALLADOLID<sup>1</sup>

<sup>1</sup>Servicio de Urgencias. <sup>2</sup>Servicio de Cardiología.  
Complejo Hospitalario de Pontevedra. Galicia.  
Spain.