

## Follicular myiasis

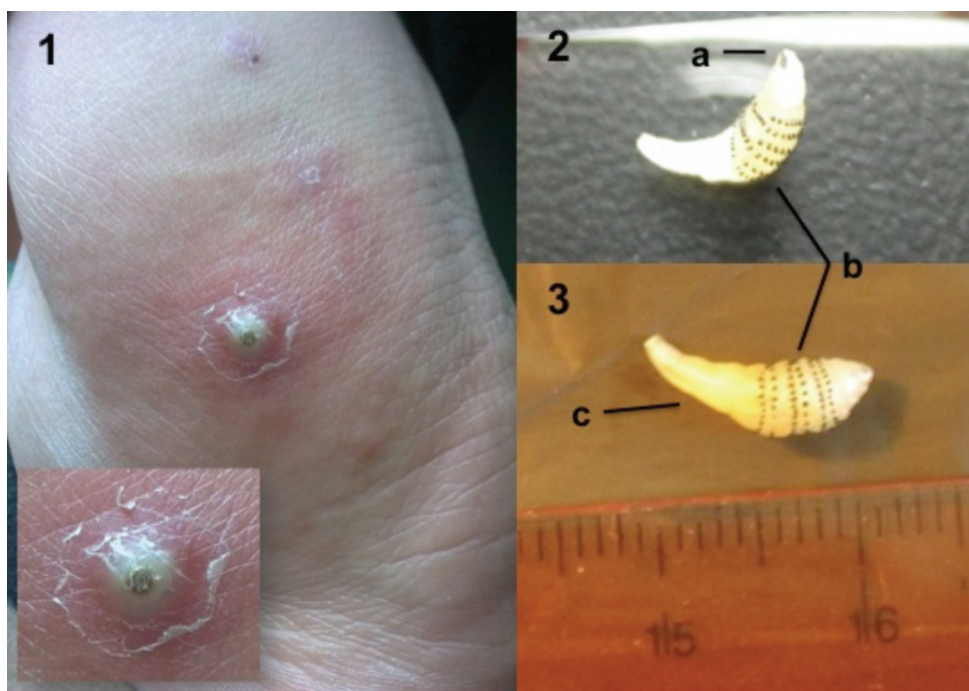
LAURA MARÍA CASTELO CORRAL<sup>1</sup>, EFRÉN SÁNCHEZ VIDAL<sup>1</sup>, MARTA PÉREZ ABELEDO<sup>2</sup>,  
Rocío VÁZQUEZ VIGO<sup>1</sup>

<sup>1</sup>Unidad de Enfermedades Infecciosas, Servicio de Medicina Interna, <sup>2</sup>Servicio de Microbiología, Complejo Hospitalario Universitario de A Coruña, Spain.

During the second week of a trip to Panama (coastal and jungle areas), a 34 year-old man noticed pruritis of the outer right ankle and knee and left buttock. After 4-6 weeks, the skin of each of these locations was elevated and hardened, developing into a painful fluctuating boil-like lesion exuding seropurulent fluid from a central hole. He manually extracted a live larva from the infected knee and consulted the emergency department. General examination and laboratory tests showed normal results. The larva was identified as *Dermatobia hominis* (human botfly).

*Furuncular myiasis* by *Dermatobia hominis* is en-

demic to Mexico and Central and South America. The adult fly captures other insects and lays its eggs on the abdomen. When the vector stings the host, the larvae are released and penetrate the skin through the sting punctum to reach subcutaneous cellular tissue where they develop during 4-14 weeks. Finally, they emerge from the skin and fall to the ground to become flies. Treatment usually involves occluding the central respiratory hole with oily substances to asphyxiate the parasite and force it out. Larvae must be removed without rupturing them to prevent hypersensitivity reactions.



**Figure 1.** Figure 1. 1: External surface of the right ankle. Furuncular lesion with seropurulent scab, central respiratory hole and erythematous base with perilesional inflammatory reaction. 2 and 3: Larvae of *Dermatobia hominis* manually extracted by the patient. a) incurved mouth hooks. b) bands of body spicules. c) abdominal segments and breathing tube.

**CORRESPONDENCE:** Laura María Castelo Corral. C/ Ángel Rebollo, 8-10, 4º Dcha. 15002 A Coruña, Spain.

E-mail: laura.castelo.corral@gmail.com

**RECEIVED:** 17-10-2011. **ACCEPTED:** 20-10-2011. **CONFLICT OF INTEREST:** None.