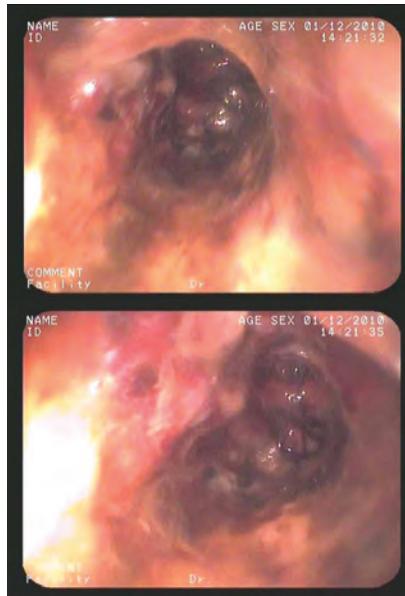


## Black esophagus as a cause of acute digestive tract hemorrhage

Sir,

Acute esophageal necrosis or "black esophagus" is a rare entity because of the generally good vasculature of the esophagus. It has been described mainly in people with nutritional deficit, septicemia or poor hemodynamic status. Clinically, it usually presents as isolated episodes of upper gastrointestinal (UGI) bleeding, with risk of perforation and, therefore, of high morbidity and mortality. The diagnosis is made by endoscopy: black lesions of the esophageal mucosa are observed, typically interrupted at the Z line level. We present a case of black esophagus diagnosed after an episode of melena and anemia.

This was a 68 year-old man with Parkinson's disease during 20 years, treated with levodopa-carbidopa, who had undergone surgery for a fractured hip one month earlier. He visited the ED for fever and pain in the surgical wound with purulent exudate during 5 days. Physical examination showed blood pressure of 112/55 mmHg, heart rate 90 bpm and mild hypohydration. Laboratory tests showed: hemoglobin (Hb) 10.3 g/dl, hematocrit 31%, leukocytes 16,000/mm<sup>3</sup> with 85% neutrophils, total protein 4.9 g/dl and serum albumin 2.7 g/dl. The remaining parameters were within normal limits. While in the ED, he presented a deposition with characteristics of melena, and Hb decrease of 2 g/dl. Urgent oral panendoscopy showed erythematous mucosa with blackish areas suggestive of necrosis as from the proximal third of the esophagus, with greater involvement of the distal third (Figure 1). The mucosa of the antrum and gastric fundus was normal, with abundant remnants of blood. Biopsy was rejected because of the risk of perforation. Chest computed tomography (CT) scan showed esophageal concentric wall thickening, distally at the carinal level, which ruled out pneumomediastinum, acute mediastinitis and aortic disease. The results of blood cultures were received 48 hours later, which coincided with those of surgical wound exudate culture, with infection by methicillin-resistant *Staphylococcus aureus* (MRSA). The patient improved during the following days, treated with parenteral nutrition, continuous infu-



**Figure 1.** Endoscopic images of the proximal (upper) and distal (lower) third displaying blackish areas corresponding to necrosis.

sion of omeprazole, intravenous meropenem and vancomycin. Transfusion with hemoderivatives was required. The patient was later hospitalized to continue treatment. Anemia necessitated further transfusion. New chest CT findings were no different. The patient's general condition then deteriorated, with hemodynamic instability, leading to death 8 days after admission.

UGI bleeding is the most frequent type of gastroenterological emergency<sup>1</sup>. It most commonly originates with peptic ulcer<sup>1</sup>, while esophageal causes range between 1.3 and 15%<sup>1,2</sup>. However, necrotic esophageal ulcers have been described in caustic poisoning, herpes infections or pharmacological lesions<sup>3</sup>.

Black esophagus, or acute necrotizing esophagitis was first described by Goldenberg et al. in two cases in the 1990s<sup>4</sup>. Precise incidence rates are not known. In autopsy series an incidence of around 0.28% has been reported<sup>5</sup>. It is more common in men, with a peak incidence in the sixth decade, more common in those with concomitant diseases such as diabetes, cancer, protein-energy malnutrition, hypertension, al-

coholism and coronary heart disease among others<sup>5</sup>. Our case reflects hypohydration, with nutritional deficit and active bacteremia secondary to prosthetic MRSA infection.

The specific etiology of this syndrome is multifactorial, although blood hypoperfusion is the most common. Thus, situations such as hypovolemia secondary to septicemia, heart failure, acute bleeding, delayed gastric emptying, hypothermia or shock have been described as precipitating factors<sup>5,6</sup>. Our patient had not been diagnosed with hiatus hernia or reflux disease, but gastrointestinal motility disorder may be assumed due to his long-standing Parkinson's disease. Also, the recent orthopedic surgery and convalescence period could have contributed to altered homeostasis. The case clearly showed ischemic necrotic lesions, more noticeable in the distal esophagus section but also visible in the proximal third. Characteristically, the lesions were interrupted at the level of the cardia<sup>5</sup>. Endoscopy in this case showed the gastric mucosa to be completely free of injury. Clinical expression is usually in the form of melena or coffee ground vomiting<sup>7</sup>.

Cases of incidental CT findings for other reasons in asymptomatic patients have been reported<sup>8,9</sup>. Other symptoms such as dysphagia, abdominal pain and vomiting may be found in some cases<sup>5</sup>. Laboratory findings include anemia and leukocytosis. Definitive diagnosis is made by endoscopy showing hyperemia of esophageal mucosa, with black areas up to the Z line. Biopsy is not necessary<sup>5</sup>. Nevertheless, the histological characteristics of black esophagus include the absence of viable epithelium, abundant necrotic tissue, abundant inflammatory infiltrate with muscle cell degeneration and the presence of micro-thrombi<sup>5</sup>. These samples must also be microbiologically analyzed to exclude other infectious etiologies. CT scan is recommended, to rule out esophageal perforation and aorto-esophageal fistulae in patients with aneurysms<sup>5</sup>. Treatment consists of absolute diet and parenteral nutrition until resolu-

tion of the picture. Broad spectrum antibiotic therapy and proton pump inhibitors are the other two pillars of therapy<sup>7</sup>. Some authors have added oral sucralfate infusion, with mixed results<sup>7</sup>. In addition to these measures, treatment directed at the accompanying diseases is necessary: restoration of blood volume, control of infection, restoration of nutritional status, etc.<sup>5,7</sup>. In our case, the new anemia that appeared during evolution was attributed to persistent or worsening necrosis, which led to hypovolemic shock. This, along with active bacteremia due to a microorganism with an aggressive course (MRSA), could explain the fatal outcome. Mortality, estimated at 35%, is mainly conditioned by underlying diseases<sup>10,11</sup>. One quarter (25%) of cases that do survive present complications, such as esophageal stenosis, which requires endoscopic dilation<sup>10</sup>.

## References

- Martínez JL, Calleja JL. Hemorragia digestiva alta: etiología y procedimientos diagnósticos. *Emergencias*. 2005;17:50-4.
- Thomopoulos KC, Vagenas KA, Vagianos CE, Margaritis VG, Blikas AP, Katsakoulis EC, et al. Changes in aetiology and clinical outcome of acute upper gastrointestinal bleeding during the last 15 years. *Eur J Gastroenterol Hepatol*. 2004;16:177-82.
- Parfitt JR, Driman DK. Pathological effects of drugs on the gastrointestinal tract: a review. *Human Pathol*. 2007;38:527-36.
- Goldenberg S, Wain S, Marignani P. Acute necrotizing esophagitis. *Gastroenterol*. 1990;2:493-6.
- Gurvits GE. Black esophagus: acute esophageal necrosis syndrome. *World J Gastroenterol*. 2010;16:3219-25.
- Ramos R, Mascarenhas J, Duarte P, Vicente C, Casteleiro C. Esofagitis necrosante aguda: análisis retrospectivo. *Rev Esp Enferm Dig*. 2008;100:583-5.
- Gurvits GE, Shapsis A, Lau N, Gualtieri N, Robilotti JG. Acute esophageal necrosis: a rare syndrome. *J Gastroenterol*. 2007;42:29-38.
- Odelowo OO, Hassan M, Nidiry JJ, Marshalleck JJ. Acute necrotizing esophagitis: a case report. *J Natl Med Assoc*. 2002;94:735-7.
- Augusto F, Fernandes V, Cremers MI, Oliveira AP, Lobato C, Alves AL, et al. Acute necrotizing esophagitis: a large retrospective case series. *Endoscopy*. 2004;36:411-5.
- Hwang J, Weigel TL. Acute esophageal necrosis: "black esophagus". *JLS*. 2007;11:165-7.
- Burtalli A, Gregoire P. Acute esophageal necrosis and low-flow state. *Can J Gastroenterol*. 21:245-7.

José A. NUEVO GONZÁLEZ<sup>1</sup>,  
Olga MARÍN CASAJÚS<sup>2</sup>,  
José MIRANDA BAUTISTA<sup>3</sup>,  
Ana I. CASTUERA GIL<sup>1</sup>

<sup>1</sup>Servicio de Urgencias, <sup>2</sup>Departamento de Medicina Interna, <sup>3</sup>Servicio de Endoscopia-Aparato Digestivo, Hospital General Universitario Gregorio Marañón, Madrid, Spain.

## Concomitant microcrystalline arthritis and septic arthritis: an important possibility to consider when evaluating of monoarthritis in the emergency department

Sir,

We have read with great interest the review of "Monoarthritis in the emergency department" by E. Revuelta<sup>1</sup>. It provides a complete and detailed presentation of the clinical management of two of the most important varieties, namely acute infectious and microcrystalline monoarthritis. We believe it is important to point out that the possibility of coexistence of both diagnoses must be considered during assessment of this syndrome. Acute monoarthritis is one of an important group of reasons for ED visits for non-traumatic musculo-skeletal disease<sup>2,3</sup>, although prevalence in our setting is not fully determined. Septic arthritis is the type of monoarthritis whose diagnosis (positive or negative) is of great interest because of the risk of joint damage, loss of function or sepsis<sup>4</sup>.

Due to its increased prevalence, microcrystalline arthritis is commonly diagnosed in clinical practice when microscopic examination under polarized light shows the presence of crystals<sup>5</sup>. In fact, the two types of monoarthritis share certain clinical and analytical characteristics: fever, synovial liquid leukocyte count above 50,000/ $\mu$ L, leukocytosis in peripheral blood and elevated acute phase reactants<sup>6</sup>. In addition, there are situations in which synovial fluid Gram stain is not diagnostic<sup>6</sup>. Finally, epidemiological characteristics that condition the diagnosis of microcrystalline arthritis include the presence of previous episodes, tophi 5 or radiological evidence of intra-articular calcification<sup>7</sup>. The coexistence of septic and microcrystalline arthritis has been described previously, although the pathophysiology underlying it remains uncertain<sup>6,8-10</sup>. It has been estimated that the prevalence of synovial fluid infection in microcrystalline monoarthritis is 5%<sup>6</sup>.

It is imperative that all synovial fluid be subjected to microbial study even when microcrystalline arthritis is predominantly suspected, as well as synovial fluid culture even when no

germs are detected by Gram stain<sup>9</sup>. The coincidence of these two pathologies remains rare, despite the greater frequency of infiltration performed in patients with inflammatory arthritis, so that there may be other mechanisms that explain it<sup>10</sup>.

## References

- Revuelta E. Monoarthritis en urgencias. *Emergencias*. 2011;23:218-25.
- Fialho SC de MS, De Castro GRW, Zimmermann AF, Ribeiro GG, Neves FS, Pereira IA, et al. Musculoskeletal system assessment in an emergency room. *Rev Bras Reumatol*. 2011;51:240-8.
- Gaieski DF, Mehta S, Hollander JE, Shofer F, Bernstein J. Low-severity musculoskeletal complaints evaluated in the emergency department. *Clin Orthop Relat Res*. 2008;466:1987-95.
- Horowitz DL, Katzap E, Horowitz S, Barilla-LaBarca M-L. Approach to septic arthritis. *Am Fam Physician*. 201;84:653-60.
- Grassi W, De Angelis R. Clinical features of gout. *Reumatismo*. 2012;63:238-45.
- Papanicolas LE, Hakendorf P, Gordon DL. Concomitant septic arthritis in crystal monoarthritis. *J Rheumatol*. 2012;39:157-60.
- Magarelli N, Amelia R, Melillo N, Nasuto M, Cantatore FP, Guglielmi G. Imaging of chondrocalcinosis: calcium pyrophosphate dihydrate (CPPD) crystal deposition disease - imaging of common sites of involvement. *Clinical and Experimental Rheumatology* [Internet]. 2012 feb 3. (Consultado 15 Febrero 2012). Disponible en: <http://www.ncbi.nlm.nih.gov/pubmed/22325558>
- O'Connell PG, Milburn BM, Nashel DJ. Coexistent gout and septic arthritis: a report of two cases and literature review. *Clin Exp Rheumatol*. 1983;3:265-7.
- Yu KH, Luo SF, Liou LB, Wu Y-JJ, Tsai WP, Chen JY, et al. Concomitant septic and gouty arthritis--an analysis of 30 cases. *Rheumatology*. 2003;42:1062-6.
- Weng C-T, Liu M-F, Lin L-H, Weng M-Y, Lee N-Y, Wu A-B, et al. Rare coexistence of gouty and septic arthritis: a report of 14 cases. *Clin Exp Rheumatol*. 2009;27:902-6.

Carlos Antonio GUILLÉN ASTETE

Servicio de Urgencias, Hospital Universitario Ramón y Cajal, Madrid, Spain.

## Kawasaki disease in an adolescent boy

Sir,

We recently attended a 14 year old boy with unremarkable medical history who visited the emergency department complaining of daily fever up to 40°C during eleven days. This was associated with fatigue, odynophagia and dysphagia with a generalized scarlatiniform rash with progressive distal peeling. He was initially treated by his family doctor with amoxicillin and ibuprofen for possible scarlet fever. Physical examination showed fever (38.8°C), diffuse erythematous rash (erythrodermic), with mi-

cropapular eruption (scarlatiniform). The eruption was most intense on the palms and soles, slightly edematous and hardened, with a hyper-chromic appearance. Peeling was faciocraneal, and on the palms and soles. He also showed purulent conjunctivitis, red lips, cracked and crusty strawberry-colored tongue with papillitis. The remainder of the physical examination was normal. Laboratory tests showed: GPT 102 mg/dL, CRP 14.7 mg/dL, ESR 63 mm, lactate 35 mg/dL, RBC  $3.92 \times 10^6/\mu\text{L}$ , Hb 12.5 g/dL, WBC  $18.4 \times 10^3/\mu\text{L}$ , platelets  $525 \times 10^3/\mu\text{L}$ , and negative mononucleosis test. The boy was admitted to the department of pediatrics, where he remained for four days to complete the study with serological tests (cytomegalovirus, Epstein Barr, herpesvirus 6, parvovirus), blood cultures, urine cultures, stool and throat cultures (all negative), and abdominal ultrasound and echocardiography (both unremarkable). With a suspected diagnosis of Kawasaki disease (KD), he was treated with IV immunoglobulins (IVIG), acetylsalicylic acid -ASA- (1 g/6 hours) and oral omeprazole, and was discharged afebrile with continuous ASA (125 mg/24 hours). The patient was readmitted on the twentieth day due to relapse, with fever and generalized rash. Imaging tests showed hydrops of the gallbladder and splenomegaly. Enzymatic alteration of liver was also found, as well as persistent eosinophilia and very high IgE values. Suspecting DRESS syndrome (Drug Rash with Eosinophilia and systemic symptoms) secondary to ASA (not confirmed later), ASA was withdrawn and clopidogrel and IV steroids were administered, resulting in clinical and laboratory test improvement within a few days.

First described by Tomisaku Kawasaki in Japan in 1961, KD is the most common cause of heart disease acquired in childhood<sup>1,4</sup>. Reported in all age groups, 80% of cases occur in children under 5 years of age and predominantly of Asian descent<sup>1-7</sup>. KD is rare in adults and diagnosis is difficult outside of children<sup>8</sup>. Of unknown etiology, epidemiological data suggest one or more infectious agents trigger an abnormal inflammatory response in genetically predisposed individuals<sup>6</sup>. The Japanese Ministry of Health established the diagnostic criteria which were then adapted by the American Heart Association and the American Academy of Pediatrics (AAP)<sup>6,7</sup> (Table 1). The disease involves self-limited panvasculitis of the small and medium size muscular arteries, with a predilection for coronary arteries<sup>3,5,7-9</sup>. Clinical manifestations usually appear sequentially, often divided into three phases: the acute phase with fever, conjunctivitis, oral erythema, erythe-

matous swelling of the hands and feet, rash, cervical lymphadenopathy, aseptic meningitis, diarrhea, liver dysfunction, myocarditis, pericardial effusion and coronary vasculitis. In the subacute phase there is distal peeling and thrombocytosis, and at this stage coronary aneurysms may occur with risk of sudden death. In the final stage, clinical signs disappear and acute phase reactants normalize<sup>3,6,7</sup>. Typical laboratory findings include leukocytosis, normocytic anemia, thrombocytosis and elevated ESR and PCR<sup>1,3,7</sup>. PCR, KD, when present in an adult, more frequently manifests with cervical lymphadenopathy, hepatitis and arthralgia<sup>8,9</sup>. Differential diagnosis includes measles, rubella, scarlet fever, streptococcal erythroderma, Stevens-Johnson syndrome, toxic shock, drug reactive eruption, leptospirosis and juvenile rheumatoid arthritis<sup>1</sup>. DRESS syndrome is a severe toxicoderma produced by drugs which could also be considered in the differential diagnosis of KD<sup>10</sup>. Although KD mortality rate is low (generally 1.25)<sup>7</sup>, if it is not treated rapidly there is a high incidence of cardiovascular damage, especially coronary<sup>6</sup>. Treatment is based on a single infusion of IVIG at 2 g/kg (the AAP recommends infusion on the 5-7<sup>th</sup> day of onset), used in combination with ASA with doses of 80-100 mg/kg/day<sup>3,6-9</sup>. Once afebrile during 48 to 72 hours, aspirin is given at antiplatelet doses of 3-5 mg/kg/day<sup>3,7,9</sup> for about six to eight weeks<sup>6,7,9</sup> or until a normal echocardiogram is obtained. Other antiplatelet agents such as clopidogrel and Ticlopidine, alone or combined with ASA, can be beneficial in some patients<sup>3,7</sup>. The use of corticosteroids is controversial; they are recommended when there is no response to IVIG<sup>3,6-9</sup>. Other treatments (cyclophosphamide or cyclosporine A associated with corticosteroids, ulinastatin) have been used with good results in small series of patients. Infliximab (antiTNF $\alpha$ ) could be considered in KD patients unresponsive to IVIG or corticosteroids<sup>3,7</sup>. There is insufficient evidence to support the use of other therapeutic proposals such as plasmapheresis, antiplatelets, pentoxifylline or statins<sup>6,7</sup>.

## References

- 1 Rowley AH, Shulman ST. Kawasaki syndrome. *Clin Microbiol Rev.* 1998;11:405-14.

**Table 1.** Kawasaki disease: criteria for clinical diagnosis<sup>6,7</sup>

Fever lasting more than five days with 4 of the following signs:

1. Bilateral conjunctival hyperemia.
2. Alterations of the lips and oral mucosa:
  - Purplish tongue.
  - Oropharyngeal rash.
  - Lips: cracked, dry, erythematous.
3. Extremity skin changes:
  - Erythema of the palms and soles.
  - Indurated edema of hands and feet.
  - Peeling fingers.
4. Polymorphous exanthema (predominantly on the trunk).
5. Cervical adenopathy (> 1.5 cm in diameter, acute, non-suppurative).

For points 2 and 3, one of the possible symptoms is sufficient.

In addition, symptoms cannot be attributed to any other well-known process.

- 2 Kushner HI, Bastian JF, Turner CL, Burns JC. The two emergencies of Kawasaki syndrome and the implications for the developing world. *Pediatr Infect Dis J.* 2008;27:377-83.
- 3 Kim DS. Kawasaki disease. *Yonsei Med J.* 2006;47:759-72.
- 4 Burns JC, Glode MP. Kawasaki syndrome. *Lancet.* 2004;364:533-44.
- 5 Barron KS. Kawasaki disease: etiology, pathogenesis, and treatment. *Cleve Clin J Med.* 2002;69(Suppl 2):69-78.
- 6 Harnden A, Takahashi M, Burgner D. Kawasaki disease. *BMJ.* 2009;338:b1514.
- 7 Newburger JW, Takahashi M, Gerber MA, Gewitz MH, Tani LY, Burns JC, et al. Diagnosis, Treatment, and Long-Term Management of Kawasaki Disease: A Statement for Health Professionals From the Committee on Rheumatic Fever, Endocarditis, and Kawasaki Disease, Council on Cardiovascular Disease in the Young, American Heart Association. *Pediatrics.* 2004;114:1708-33.
- 8 Wolff AE, Hansen KE, Zakowski L. Acute Kawasaki disease: not just for kids. *J Gen Intern Med.* 2007;22:681-4.
- 9 Gomard-Mennesson E, Landron C, Dauphin C, Epaulard O, Petit C, Green L, et al. Kawasaki disease in adults: report of 10 cases. *Medicine.* 2010;89:149-58.
- 10 Hughey LC. Fever and erythema in the emergency room. *Semin Cutan Med Surg.* 2007;26:133-8.

Manuel CUESTA MARTÍN,  
Javier OÑATE ADRIÁN

*Servicio de Urgencias, Hospital de Cruces,  
Baracaldo, Vizcaya, Spain.*

## Syncope and sinus bradycardia in a cocaine and cannabis user

Sir,

Cardiovascular complications of cocaine use are well defined<sup>1</sup>, although bradyarrhythmia has scarcely been mentioned<sup>2</sup>. Cocaine consumption is not generally considered in the differential diagnosis of syncope<sup>2</sup>.



A 31 year-old woman, a cocaine and cannabis consumer, with otherwise unremarkable history, was referred to the emergency department after an episode of syncope. Out-of-hospital medical attention had noted a blood pressure (BP) of 95/55 mmHg and heart rate (HR) of 45 bpm. On arrival at the emergency department, the patient was asymptomatic and had no chest pain, palpitations or dyspnea. There was no history of syncope. She admitted having consumed cocaine and cannabis in the previous hours. On physical examination, she was afebrile, with BP 97/70 mmHg, HR 46 bpm, and arterial oxygen saturation was 100%. Blood test was normal, and urine tested positive for cocaine and cannabis metabolites. ECG showed sinus rhythm of 58 bpm, first degree atrioventricular block and QTc of 416 ms. Cranial CT scan was normal. The patient was kept under observation for 10 hours. The ECG at discharge showed: normalized intraventricular conduction with a QTc interval of 379 msec.

Syncope is a transient loss of consciousness with spontaneous recovery, without chemical or electric cardioversion. The etiology may be neurological, metabolic, psychiatric or cardiac. Cardiopathy is the most common and is associated with the highest mortality rate<sup>3</sup>.

Cocaine consumption in Spain accounts for 28.6-66% of emergency visits for substances of abuse<sup>4,5</sup>. Elec-

trocardiographic changes secondary to consumption include elongation of the QTc interval<sup>6</sup>. Arrhythmias, with extreme heart rates, may depress cardiac output to produce syncope<sup>1</sup>. Sodium channel blockade is the major reason for cocaine-users predisposition to arrhythmia<sup>7</sup>, although the mechanism whereby brady-arrhythmia is produced is not well known. Cocaine can depress sinus node automaticity and cause AV node conduction block<sup>8</sup>. Other factors may include localized sinoatrial artery spasm, inferior myocardial infarction, vagal stimulation during inhalation and direct toxic effect<sup>2</sup>. The consumption of cannabis can cause bradycardia and hypotension due to decreased sympathetic tone<sup>9</sup>. In our case, the association of cocaine and cannabis could have enhanced the bradycardia effect and caused the syncope, although it is possible there may have been QTc interval prolongation with ventricular tachycardia of the torsade de pointes type as the cause of syncope, which subsequently reverted to sinus bradycardia. Emergency physicians should be aware of this association, especially when evaluating syncope in young people. Toxicological analysis should be indicated in the evaluation of syncope in certain circumstances.

## References

- 1 Mouhaffel AH, Madu EC, Satmary WA, Kosinski DJ. Cardiovascular complications of cocaine. *Chest*. 1995;107:1426-34.
- 2 Castro VJ, Nacht R. Cocaine-induced bradyarrhythmia. An unsuspected cause of syncope. *Chest*. 2000;117:275-7.
- 3 Kessler C, Triatano JM, De Lorenzo R. The emergency department approach to syncope: evidence-based guidelines and prediction rules. *Emerg Med Clin North Am*. 2010;28:487-500.
- 4 Galicia M, Nogué S, Sanjurjo E, Miró O. Evolución de las consultas urgentes relacionadas con el consumo de cocaína durante el periodo 2002-2007. *Emergencias* 2008;20:385-90.
- 5 Caballero Vallés PJ, Dorado Pombo S, Díaz Braseró A, García Gil ME, Yubero Salgado L, Torres Pacho N, et al. Vigilancia epidemiológica de la intoxicación aguda en el área sur de la comunidad de Madrid: estudio Veia 2004. *An Med Interna (Madrid)*. 2008;25:67-72.
- 6 Muñoz J. Síndrome de QT largo y torsade de Pointes. *Emergencias*. 2004;16:85-92.
- 7 Wood DM, Dargan PI, Hoffman RS. Management of cocaine-induced cardiac arrhythmias due to cardiac ion channel dysfunction. *Clin Toxicol*. 2009;47:14-23.
- 8 Om A, Ellenbogen K, Vetrovec G. Cocaine-induced bradyarrhythmias. *Am Heart J*. 1992;124:232-4.
- 9 Jones RT. Cardiovascular system effects of marijuana. *J Clin Pharmacol*. 2002;42:585-635.

Anna REY,  
August SUPERVÍA,  
Alfons AGUIRRE,  
José Luis ECHARTE

*Servicio de Urgencias, Hospital Universitario del Mar, Barcelona, Spain.*